

# Functional neuroanatomy of remote episodic, semantic and spatial memory: a unified account based on multiple trace theory

Morris Moscovitch,<sup>1,2</sup> R. Shayna Rosenbaum,<sup>2</sup> Asaf Gilboa,<sup>2</sup> Donna Rose Addis,<sup>1,3</sup> Robyn Westmacott,<sup>3</sup> Cheryl Grady,<sup>1,2</sup> Mary Pat McAndrews,<sup>1,3</sup> Brian Levine,<sup>1,2</sup> Sandra Black,<sup>1,2,4</sup> Gordon Winocur<sup>1,2,5</sup> and Lynn Nadel<sup>6</sup>

<sup>1</sup>University of Toronto, Canada

<sup>2</sup>Baycrest Centre for Geriatric Care, Toronto, Canada

<sup>3</sup>Toronto Western Hospital, Department of Neuropsychology, 399 Bathurst St., Toronto ON, M5T 2S8, Canada

<sup>4</sup>Sunnybrook and Women's Hospital, Department of Neurology, 2075 Bayview Avenue, Toronto, Ontario M4N 3M5, Canada

<sup>5</sup>Trent University, Department of Psychology, 1600 West Bank Drive, Peterborough, Ontario, K9J 7B8, Canada

<sup>6</sup>University of Arizona, Department of Psychology, Moll & Cherry St., AZ 85721, Tucson, USA

---

## Abstract

We review lesion and neuroimaging evidence on the role of the hippocampus, and other structures, in retention and retrieval of recent and remote memories. We examine episodic, semantic and spatial memory, and show that important distinctions exist among different types of these memories and the structures that mediate them. We argue that retention and retrieval of detailed, vivid autobiographical memories depend on the hippocampal system no matter how long ago they were acquired. Semantic memories, on the other hand, benefit from hippocampal contribution for some time before they can be retrieved independently of the hippocampus. Even semantic memories, however, can have episodic elements associated with them that continue to depend on the hippocampus. Likewise, we distinguish between experientially detailed spatial memories (akin to episodic memory) and more schematic memories (akin to semantic memory) that are sufficient for navigation but not for re-experiencing the environment in which they were acquired. Like their episodic and semantic counterparts, the former type of spatial memory is dependent on the hippocampus no matter how long ago it was acquired, whereas the latter can survive independently of the hippocampus and is represented in extra-hippocampal structures. In short, the evidence reviewed suggests strongly that the function of the hippocampus (and possibly that of related limbic structures) is to help encode, retain, and retrieve *experiences*, no matter how long ago the events comprising the experience occurred, and no matter whether the memories are episodic or spatial. We conclude that the evidence favours a multiple trace theory (MTT) of memory over two other models: (1) traditional consolidation models which posit that the hippocampus is a time-limited memory structure for all forms of memory; and (2) versions of cognitive map theory which posit that the hippocampus is needed for representing all forms of allocentric space in memory.

**Key words** hippocampus; medial temporal lobes; episodic memory; spatial memory; semantic memory; consolidation; multiple trace theory.

---

## Correspondence

Morris Moscovitch, Department of Psychology, University of Toronto and Rotman Research Institute – Baycrest Centre, Toronto, Ontario, Canada M5S 3G3. T: 416-978-7815; F: 416-978-4811; E: momos@psych.utoronto.ca

Accepted for publication March 15, 2005

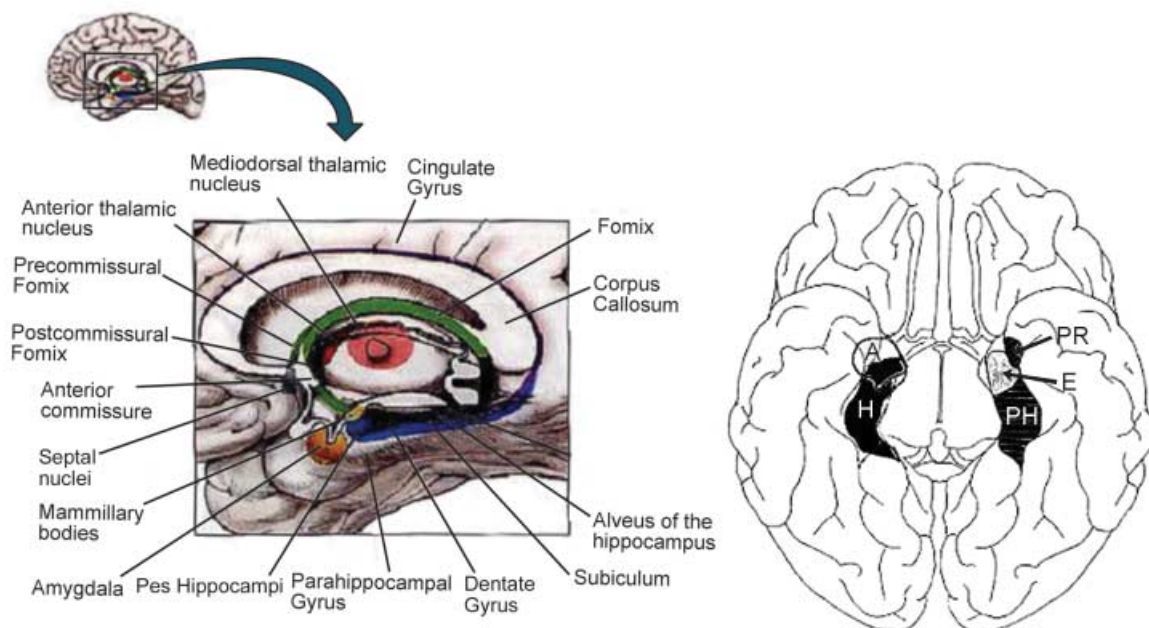
'The fixing of an impression depends on a physiological process. It takes time for an impression to become so fixed that it can be reproduced after a long interval; for it to become part of the permanent store of memory considerable time may be necessary. This we may suppose is not merely a process of making a permanent

impression upon the nerve cells, but also a process of association, of organization of the new impressions with the old ones.' Burnham (1904), p. 128.

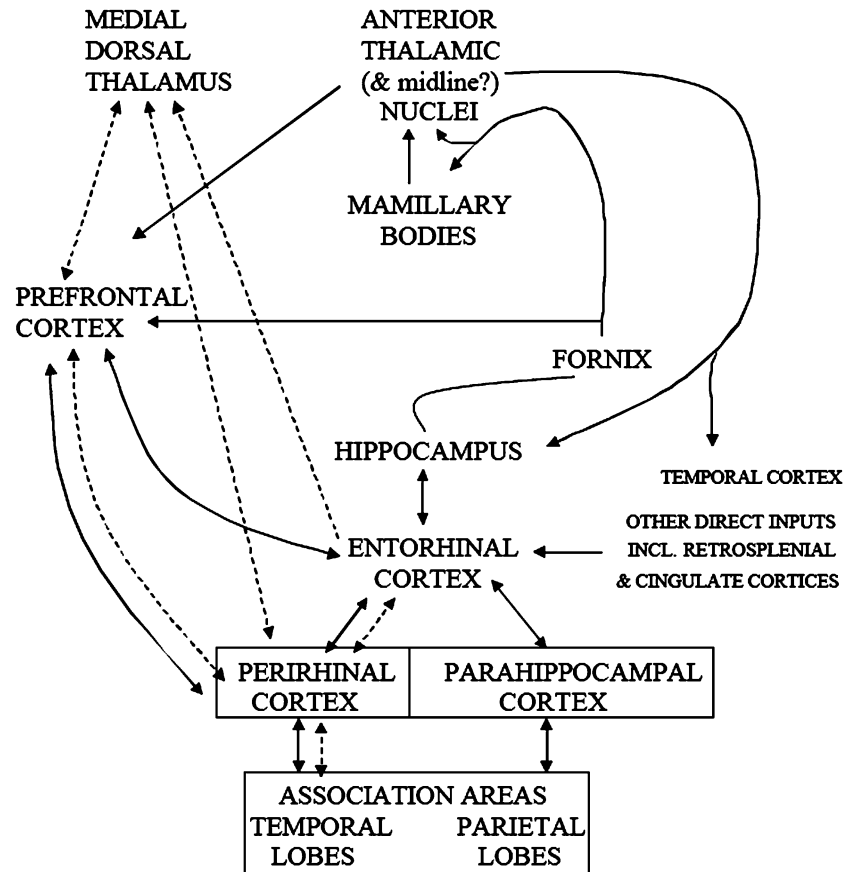
Though writing in 1904, Burnham could already draw on a substantial literature on the nature of memory that had accumulated during what Rozin (1976) called 'The Golden Age' of memory research at the turn of the 20th century. It was then that the scientific study of memory began. Many of the problems confronting memory researchers were identified and programs of research to address those problems were outlined and initiated. The term 'consolidation' was introduced at that time by Müller & Pilzecker (1900) to describe a time-dependent process needed to assimilate an experience and store it permanently as a memory which is relatively immune to disruption. Integrating what was known at that time, Burnham identified two processes implicated in consolidation: (1) a physiological or biochemical process needed for formation and storage of a memory trace or *engram* (Semon, 1922, cited in Schacter et al. 1978); and (2) a psychological process needed to assimilate the newly acquired memory into an already existing body of knowledge, and to allow it, in turn, to influence what will be learned subsequently. Elucidating these processes remains at the heart of research on memory and consolidation, and will be the

focus of this paper. In particular, we wish to examine three types of memory – autobiographical, semantic and spatial – and investigate what studies of remote memory can tell us about the neural substrates mediating them, and how they may be modified with time. In doing so, we hope to unify episodic, semantic and spatial memory in a single framework that accounts for similarities and differences between them.

The modern era of research into the neural substrates of memory was ushered in by Scoville & Milner's publication on the effects of excision of the anterior and medial temporal lobes bilaterally to control intractable epilepsy in a single patient, H.M. (Scoville & Milner, 1957). The excision included large portions of the *hippocampal complex* (see also Corkin et al. 1997), whose terminology can be quite confusing (see Figs 1 and 2). The *hippocampus proper* includes the CA fields and dentate gyrus. The *hippocampal formation* includes the *hippocampus proper* and also incorporates the subiculum; the *hippocampal complex* further includes the parahippocampal region, which incorporates the entorhinal, the perirhinal and the parahippocampal cortices. Though the surgery was effective in controlling his epilepsy, one of its unanticipated consequences was that H.M. became profoundly amnesic, while retaining his intelligence, perceptual and motor functions. The memory loss characterizing his amnesia was



**Fig. 1** Left panel: Medial temporal lobe structures and their connections viewed from the side (sagittal section). (Adapted from Blumenfeld, 2002.) Right panel: Medial temporal lobe structures viewed from the underside of the brain. A, amygdala; E, entorhinal cortex; H, hippocampus; PH, parahippocampal cortex; PR, perirhinal cortex.



**Fig. 2** The hippocampal-diencephalic systems showing connections between medial temporal structures and diencephalic (thalamic) nuclei and frontal lobes. Solid lines show the extended hippocampal system, presumed to mediate recollection, and dotted lines show the extended perirhinal system, presumed to mediate familiarity. (Modified from Aggleton & Brown, 1999.)

typical of that observed in other patients with medial temporal lobe damage who were studied subsequently, and in many people with organic amnesia of different etiologies that affected mid-line thalamic nuclei (see Aggleton & Brown, 1999; Fig. 2). Though lacking substantial portions of the medial temporal lobes or crucial diencephalic nuclei, these individuals had normal short-term memory, as measured by a number of tests, including digit-span performance that involves repeating back a series of numbers. Similarly, it was reported that deficits in remote memory were limited to retrieval of events within the past few years, suggesting that older memories, both autobiographical and semantic, were stored, and could be retrieved readily, without the medial temporal lobes (Milner, 1966; Corkin, 1984). These observations were interpreted as showing that the medial temporal lobes and related diencephalic structures were not involved in processing short-term memories or in storing remote memories. Instead, their function was to help consolidate memories in other brain regions, and to encode, store and retrieve them until consolidation was complete (Squire, 1992). The standard model of consolidation

was based on these initial observations and has been modified little since then (for a brief review of amnesia, see Milner et al. 1998; Moscovitch, 2001).

Evidence accumulated in recent years, however, has not always been consistent with the standard model of consolidation; nor, in retrospect, is some of the older evidence (see Corkin, 2002; Steinvorh et al. 2005 for an update on H.M. and the initial descriptions of remote memory loss in Penfield & Milner, 1958, and the review by Nadel & Moscovitch, 1997). Neuroanatomical and functional considerations are at the core of the discrepancy concerning consolidation and the representation of remote memories in the brain. To help the reader appreciate better the recent developments and the debate concerning both consolidation and remote memory, the standard model is presented and critically reviewed briefly. It is then compared with an alternative, multiple trace theory (MTT), against the neuropsychological evidence from studies in patients with focal lesions or degenerative disorders, and from functional neuroimaging studies in people who are neurologically intact (for a fuller exposition, see Moscovitch, 2001; Moscovitch et al. 2005).

## The standard model of consolidation

According to the standard model (Squire & Alvarez, 1995; Dudai, 2004; McGaugh, 2000), memory consolidation begins when information, registered initially in the neocortex, is integrated by the hippocampal complex/medial temporal lobes (HC/MTL) and related structures in the diencephalon to form a memory trace that consists of an ensemble of bound hippocampal complex–neocortical neurons (Moscovitch, 1995, 2000). This initial binding into a memory trace involves short-term processes, the first of which may be completed within seconds and the last of which may be completed within minutes or, at most, days. We refer to the latter as *rapid or synaptic consolidation or cohesion* (Moscovitch, 1995; Dudai, 2004). The existence of rapid consolidation is not in dispute. Indeed, much has been learned about its cellular and neurochemical (molecular) basis, which seem to be similar across species and across different memory systems in the same species. Excellent, brief reviews of this topic can be found in Kandel (2001) and McGaugh (2000, 2004) and will not be considered further in this paper.

A process of *prolonged or system consolidation* (Burnham, 1904; Dudai, 2004; Frankland & Bontempi, 2005) is then believed to occur, which may last for months and even decades. According to the standard model, during this process, the HC/MTL and related structures are needed for storage and recovery of the memory trace, but their contribution diminishes as consolidation proceeds, until the neocortex (and possibly other extra-hippocampal structures) alone is capable of sustaining the permanent memory trace and mediating its retrieval. Thus, the HC/MTL and related structures are considered by the standard model to be temporary memory systems, needed to store and retrieve memories only until prolonged consolidation is complete. The time it takes for consolidation to be complete corresponds to the temporal extent of retrograde amnesia following lesions of the HC/MTL and diencephalon, other insults (concussions, closed head injuries or electrical currents), or the administration of pharmacological agents that disrupt memory permanently.

In contrast to rapid consolidation, not only are we far from understanding the mechanisms mediating prolonged consolidation, which includes the psychological processes that Burnham and others (Squire et al. 1984) emphasized but, as we shall see, the very existence of this process is in doubt, at least for some types of

memory. In the 1960s, the outlines of the central debate concerning the validity of the standard model already were crystallized clearly in work with amnesic patients (Warrington & Weiskrantz, 1970; Warrington & Sanders, 1971). The debate continues to centre on the following four questions. (1) What types of memory are implicated? (2) Which neuroanatomical structures in the medial temporal lobes and diencephalon are involved? (3) What is the extent and duration of retrograde amnesia, and, by implication, of consolidation, and how is it affected by lesion location and memory type? (4) What other structures outside the medial temporal lobe and diencephalon contribute to retention and retrieval of remote memory? The first two questions presuppose the existence of different memory systems with different rules of operation and different neuroanatomical substrates. We will deal with the first two questions in turn, and the third and fourth will be addressed in the course of discussing the first two.

## Memory types and their neuroanatomical substrates

### Explicit and implicit memory

One of the major discoveries of memory researchers in the latter part of the 20th century, arguably a second ‘Golden Age’ of memory research, is that memory is not unitary but consists of various types, each influenced by different variables, governed by different principles, possibly concerned with different materials, and each mediated by different neural structures and mechanisms that form distinguishable, and dissociable, systems (see Milner et al. 1968; Warrington & Weiskrantz, 1970; Milner, 1974; O’Keefe & Nadel, 1978; Weiskrantz, 1980; Cermak, 1982; Moscovitch, 1992, 2001; Schacter & Tulving, 1994; Tulving & Craik, 2000). Two broad classes of memory were identified: *explicit memory*, which refers to conscious recollection of experiences and facts (sometimes called *declarative memory*; Cohen & Squire, 1980; Squire, 1992); and *implicit or nondeclarative memory* (Schacter, 1987), which is memory without awareness that is revealed by the effects of prior experience on behaviour without the individual consciously retrieving the memory or even being aware of having it. Examples of implicit memory are: perceiving a picture or a face more quickly after it was seen, though the person may deny that the face or word was familiar (perceptual priming); learning a repeated, complex motor sequence, even though

the individual may not be aware of the sequence or that it was repeated (procedural memory); or learning to form conditioned responses, though the individual may not be aware of the stimuli controlling the response (conditioning; see Moscovitch et al. 1993; Roediger & McDermott 1993).

Whereas the HC/MTL is crucial for explicit memory, it is not needed for implicit memory. Many, if not all, types of implicit memory can be acquired, retained and retrieved normally even by people who are profoundly amnesic as a result of HC/MTL or diencephalic damage. It is believed that implicit memory is mediated by the neural structures involved in acquiring information, such as the posterior neocortex for perception of objects, faces and words such and the basal ganglia for execution of motor sequences (for reviews, see Tulving & Schacter, 1990; Moscovitch et al. 1993; Schacter & Buckner, 1998; Wiggs & Martin, 1998; Schacter & Badgaiyan, 2001; Schacter et al. 2004). Because we know little about prolonged consolidation effects in implicit memory, our discussion will be restricted to explicit memory.

#### **Explicit memory: functional distinctions between episodic memory, familiarity and semantic memory**

Explicit memory is itself divisible into two types: episodic and semantic (Tulving, 1972). *Episodic memory* refers to memory for particular autobiographical episodes or specific events in the life of the individual, which includes information about both the content of the experience and the spatial and temporal context in which it occurred. Having such a memory entails a detailed re-experiencing of the initial event, effectively allowing one to travel mentally back in time (Tulving, 1985). In studies of anterograde memory, episodic memory is assessed by tests of *recollection*, which refers to representation of past experiences and includes not only the content of those experiences but also their spatial-temporal context, all of which, Tulving (1985) proposed, depends on auto-noetic consciousness (consciousness with the self in it). Building on Tulving's distinction, Moscovitch (1995, 2000) emphasized that episodic memory also includes the *conscious experience* accompanying the episode. Put succinctly, episodic memory refers to memory of the *experience* of the event, of which conscious awareness is a part.

*Semantic memory* refers to the noncontextual content of experience, or knowledge about the world acquired during experience, which contributes to the

formation and long-term representation of concepts, categories, facts, word meanings, and so on. It even includes knowledge about ourselves (where we were born, where we lived, who our friends were, what schools we attended, what jobs we held), what some have called *personal semantics* (Cermak & O'Connor, 1983; Kopelman et al. 1989) to distinguish this memory from that for autobiographical episodes (for a discussion and examples of different tests used to assess different types of memory, see Kopelman et al. 1989; Moscovitch et al. 1999; Fujii et al. 2000; Nadel & Moscovitch, 2001). Unlike episodic, autobiographical memory, semantic memory is associated only with noetic consciousness, which is consciousness of knowledge without a sense of self and experience accompanying it.

A third type of memory, *familiarity*, shares attributes with episodic and semantic memory. It refers to memory of stimuli, rather than of events, which one recognizes as familiar but for which one has no recollection of the context in which the stimuli occurred, as happens when one encounters a person who is familiar without being able to place the person. Like semantic memory, familiarity is associated with noetic consciousness. Following Tulving's proposal, which itself builds on earlier work by Atkinson & Juola (1973) and Mandler (1980) on tests of anterograde memory, familiarity is assessed by recognition devoid of recollection. Since Tulving's initial proposal, a number of procedures have been used to distinguish recollection from familiarity in tests of anterograde memory, each having its own virtues and liabilities, but all share the assumption that different processes and, possibly representations, distinguish the two types of memory (for review and critique, see Yonelinas, 2002 and Rotello et al. 2004).

#### **Neuroanatomical substrates associated with different types of explicit memory**

Developments concerning the functional properties of types of anterograde memory were accompanied by advances in our appreciation of the neural substrates mediating them. After reviewing the effects of lesions to different parts of the hippocampal complex, and the thalamic structures with which they are associated, Aggleton & Brown (1999), building on earlier proposals by Eichenbaum et al. (1994), proposed a division into two systems. One system, consisting of the hippocampus and its connections to the mammillary bodies and anterior thalamic nuclei (the extended hippocampal

system), is presumed to mediate recollection relying on relational information, including the temporal–spatial context of the memory (see Figs 1 and 2). Damage to this system causes deficits in spatial memory and in memory for relational information that typifies memory for autobiographical episodes, but spares recognition based only on familiarity (Aggleton et al. 2000; Holdstock et al. 2002a; Mayes et al. 2003, 2004; D. Moscovitch & McAndrews, 2002; Yonelinas, 2002; Yonelinas et al. 2002).

The other system, consisting of the perirhinal cortex and its connections to the dorsomedial nucleus of the thalamus (the extended perirhinal system), is necessary for item recognition based on familiarity which does not require access to spatial-temporal context (see Fig. 2). Damage to this system will impair recognition even of single items (Aggleton et al. 2000). The parahippocampal cortex seems to be necessary for forming memories of places (Epstein & Kanwisher, 1998; Epstein et al. 1999, 2003) or of associating objects with particular locations (Owen et al. 1996a,b), and may provide the allocentric, spatial framework for recollection (O'Keefe & Nadel, 1978; Nadel & Moscovitch, 1997; Burgess et al. 2001, 2002; Rosenbaum et al. 2004a).

Semantic memory, on the other hand, does not depend on medial temporal and diencephalic structures, though it may benefit from them at acquisition; rather, semantic memory is mediated by a network of posterior and anterior neocortical structures, depending on the particular attributes of the memory. Typically, the structures mediating semantic memory include the lateral and anterior temporal cortex, and ventro-lateral prefrontal cortex, usually on the left (for reviews, see Graham et al. 1999; Tranel et al. 1997; Martin & Chao, 2001; Thompson-Schill, 2003).

### Functional distinctions and neuroanatomical substrates of remote memory

Of all of these types of memory, only the investigation of semantic memory seems to be concerned with information acquired outside the laboratory. Semantic memory refers to one's general knowledge, which is presumed to be entrenched before laboratory investigation of it begins. There is general agreement that semantic memory can survive HC/MTL damage (see Moscovitch et al. 2005), though it initially may benefit from the contribution of those structures. What is disputed is whether episodic memory, either autobiographical or only familiarity-based, is dependent permanently or only temporarily (until

consolidation is complete) on the HC/MTL. Put another way, do the structures implicated in recollection and familiarity for anterograde memory retain their function for remote memory, or do they relinquish their support once consolidation is complete, with the *very same* memories becoming represented only in neocortex?

### Spatial memory: distinguishing between detailed (episodic) and schematic (semantic) spatial memory

Spatial memory sometimes is considered in the context of episodic memory (O'Keefe & Nadel, 1978; Burgess et al. 2002), but rarely in the context of semantic memory, because it seems to be orthogonal to this category. For the purposes of this paper, however, we will divide spatial memory into categories analogous to those in explicit memory, to see what can be gained from such a classification. We propose that it is useful to distinguish between those spatial memories that consist of *detailed perceptual–spatial representations* of experienced environments (corresponding to episodic, autobiographical memory) and those that consist of *schematic representations of the topography* (corresponding to semantic memory). The detailed representations consist not only of allocentric and egocentric information about routes and maps of the environment and of the location of major landmarks, that is the topography of the environment, but also of the appearance of the elements of which the environment is comprised, such as houses, parks, lawns, fields, hills, and so on. Such detailed representations effectively consist of vividly remembered routes and scenes which would allow one to re-experience the environment as one takes a mental walk through it, a spatial analogue of mental time travel, and to recognize its various attributes on formal tests. By contrast, schematic, topographical representations or cognitive maps are sufficient to allow one to navigate in the environment and recognize only those features which provide salient cues for navigation, without supporting a rich representation and re-experiencing of the environment, or even recognition of elements not crucial for navigation (see Rosenbaum et al. 2000, 2001 for earlier versions of this view, and Rosenbaum et al. 2004a, 2005). For ease of exposition, we refer to the perceptually or experientially detailed representations as *detailed or vivid spatial memories*, which captures the experiential component in addition to details, and to the schematic representations as *schematic spatial memories*.

There is general agreement that the HC/MTL is needed for acquisition of allocentric spatial memory, whether detailed or schematic (Burgess et al. 2002), but there has been little research on whether the HC/MTL is needed for retention and retrieval of remote spatial memories of either type. The evidence we review suggests, as with autobiographical memory, that schematic (semantic) spatial memories can survive damage to HC/MTL, but that perceptually detailed (episodic) spatial memories cannot.

### **The MTL, neocortex and predictions based on the standard model: retrograde amnesia is equivalent across all memory types**

According to the standard model of consolidation, no distinction is drawn with respect to consolidation among different types of explicit memory, be they spatial or nonspatial, episodic or semantic, recollective or familiar (Squire & Zola, 1998; Squire et al. 2004) – all are dependent on the HC/MTL for the duration of the consolidation period, after which they can be retained and retrieved independently of it. Thus, damage to the HC/MTL and diencephalon leads to a graded, temporally limited retrograde amnesia for both episodic and semantic memory, whether autobiographical or spatial. Memories acquired most recently are most severely affected, with more remote memories being retained normally, having been fully consolidated before the insult (see Squire, 1992; Squire & Alvarez, 1995). The data, however, do not consistently support the model.

### **Problems with the standard model: retrograde amnesia for episodic (including spatial) memory is prolonged and for semantic (including spatial) memory is relatively preserved**

The standard model of consolidation had been challenged by Warrington and colleagues, who showed that retrograde amnesia can be severe and of long duration following HC/MTL lesions (Warrington & Sanders, 1971; Warrington & McCarthy, 1988; Warrington, 1996). Kinsbourne & Wood (1975) suggested that retrograde amnesia is a deficit only of episodic (autobiographical) memory, which affects recent and remote memory equally. Although few endorsed their ideas at the time (see Moscovitch, 1982; Nadel & Moscovitch, 1997; Fujii et al. 2000; Nadel et al. 2000, 2003), recent reviews revitalized them, and argued that the evidence favoured them.

Nadel & Moscovitch identified a number of problems with the standard model, both with respect to the types of memory that are affected, and with the duration and extent of retrograde amnesia. They noted that retrograde amnesia varied with memory type, decreasing in severity and extent from the autobiographical to the semantic. Retrograde amnesia for episodic memory, the details of autobiographical events, after large medial temporal (or diencephalic) lesions can extend for decades, or even a lifetime, far longer than it would be biologically plausible for a consolidation process to last. Retrograde amnesia for semantic memory, however, is less extensive and often is temporally graded as is the case for memory of public events and personalities, and even more so for vocabulary and for facts about the world and oneself (personal semantics; Fujii et al. 2000; see also Kapur, 1999 for an extensive review of retrograde amnesia). Thus, contrary to the standard model, nonspatial semantic and episodic memories are affected differently by lesions producing retrograde amnesia (see Warrington, 1996). As we see below (see section on *Spatial Memory*, pp. 54–59), the same is true of spatial memory.

### **Multiple trace theory: an alternative to the standard model**

To account for this evidence, Nadel & Moscovitch (1997) proposed a multiple trace theory (MTT) of memory. According to this theory, the hippocampal complex (and possibly the diencephalon) rapidly and obligatorily encodes all information that is attended (consciously apprehended; Moscovitch & Umiltà, 1990; Moscovitch, 1992) and binds the neocortical (and other) neurons that represent that experience into a memory trace. This information is sparsely encoded in a distributed network of hippocampal complex neurons that act as a pointer, or index, to the neurons representing the attended information (Teyler & DiScenna, 1986). A memory trace of an episode, therefore, consists of a bound ensemble of neocortical and HC/MTL (and possibly diencephalic) neurons which represent a memory of the consciously experienced event. As noted earlier, formation and consolidation of these traces, or cohesion (Moscovitch, 1995), is relatively rapid, lasting on the order of seconds or at most days.

In this model, there is no prolonged consolidation process, as the standard model asserts, that slowly

strengthens the neocortical component of the memory trace, so that with time the trace becomes independent of the HC/MTL. Instead, each time an old memory is retrieved, a new hippocampally mediated trace is created so that old memories are represented by more or stronger HC/MTL–neocortical traces than are new ones and, therefore, are less susceptible to disruption from brain damage than are more recent memories. Because the memory trace for autobiographical episodes is distributed in the HC, the extent and severity of retrograde amnesia, and perhaps the slope of the gradient, are related to the extent and location of damage to the extended hippocampal system.

Whereas each autobiographical memory trace is unique, the creation of multiple, related traces facilitates the extraction of the neocortically mediated information common among them, and which is shared with other episodes. This information is then integrated with pre-existing knowledge to form semantic memories that can exist independently of the HC/MTL. Thus, knowledge about the world, about people and events acquired in the context of a specific episode is separated from the episode and ultimately stored independently of it. This process of increased *semanticization* with experience and retrieval over time may give the impression of prolonged consolidation of the original trace (see section on *Semantic Memory*, pp. 51–54). Without a well-functioning hippocampal system, acquisition of semantic memory is slow and effortful, at least in adulthood. It is possible, however, that in childhood, structures mediating semantic memory, such as those involved in language learning, can form new representations easily without benefit of the hippocampus (Vargha-Khadem et al. 1997).

With respect to spatial memory, the issue is whether the hippocampus is crucial for retention and retrieval of allocentric, spatial information, no matter how long ago it was acquired. According to cognitive map theory, the hippocampus is crucial, and it provides the spatial context of autobiographical memory. Another view, less consistent with the initial formulation of cognitive map theory, but quite compatible with MTT, is that only detailed, episodic spatial information, directly linked to the re-experiencing of an event, is mediated by the hippocampus. Generic allocentric spatial information necessary for navigation, what we have termed schematic (semantic) spatial memory, is mediated initially by the hippocampus, but like other

forms of semantic memory, can exist independently of it once the memory has been assimilated.

### **Differences between MTT and the standard model: neuroanatomical and functional considerations**

#### **Episodic (nonspatial) memory and the role of the HC/MTL and related structures**

Defenders of the standard model argue that lesion location and size, as much as type and test of memory, need to be taken into account in considering the extent and severity of retrograde amnesia. The initial studies on retrograde amnesia (Scoville & Milner, 1957; Penfield & Milner, 1958; Milner, 1966; Mair et al. 1979) implicated the HC/MTL and diencephalon (see Figs 1 and 2). The focus of attention, however, shifted quickly to the hippocampal formation, and then to the hippocampus itself (Squire, 1975, 1992; Squire et al. 1984). The current position is that temporally limited memory applies only to the hippocampus and that permanent memories are consolidated either in the adjacent regions of the HC/MTL or in the lateral temporal neocortex (Rempel-Clower et al. 1996; Reed & Squire, 1998; Squire & Zola, 1998; Bayley et al. 2003; Manns et al. 2003).

The evidence, reviewed by Nadel, Moscovitch and their colleagues (Nadel & Moscovitch, 1997; Fujii et al. 2000; Nadel et al. 2003), favoured the older idea that the entire HC/MTL region is implicated in retention and retrieval of remote memory. They noted that the extent and severity of retrograde amnesia depended on the size of the medial temporal lesion: the larger the lesion, the greater the loss. As importantly, Nadel & Moscovitch distinguished among different types of explicit memory, with episodic, autobiographical memory being the most severely affected, and semantic memory, the least. Given the multifaceted nature of episodic memory in general, and autobiographical episodes in particular, Nadel & Moscovitch (1997, 1998) suggested that each of the various regions of the medial temporal lobe may contribute its own information to the complete, detailed memory of an event, although they left the precise formulation vague. As we have learned more about the separate functions of medial temporal regions (Aggleton & Brown, 1999), it may make sense to consider the possibility that each of them is involved in retention and retrieval of those aspects of an event which they specifically process



(Gilboa, 2004a; Gilboa et al. 2005 submitted). Thus, for remote memory, as for anterograde memory, recollection of autobiographical episodes, the full re-experiencing of an event, will always depend on the hippocampus. Recognition of objects based on familiarity, and generic personal memories, can survive hippocampal damage, but not damage to perirhinal cortex, whereas recognition of aspects of places will be impaired following parahippocampal gyrus lesions, and of emotions, following amygdala lesions. In addition, in recollecting an autobiographical episode, damage to these structures should lead to loss of the information mediated by these extra-hippocampal structures.

### **Semantic (nonspatial) memory: neocortical–hippocampal interactions**

*Semantic memory*, on the other hand, depends on neocortical structures that are sufficient to form domain-specific and semantic representations based on regularities extracted from repeated experiences with words, objects, people and environments (Westmacott et al. 2001; Rosenbaum et al. 2004a). This applies even to autobiographical episodes one recollects repeatedly, thereby creating a gist of each episode which lacks the details that makes rich re-experiencing possible. The MTL system may aid in the initial formation of these neocortical representations (Nadel & Moscovitch, 1997), but, once formed, they can exist on their own (Fujii et al. 2000). Because autobiographical memory consists of a hierarchical structure which includes generic semantic information, as well as event-specific information (for more detail, see Conway & Fthenaki, 2000; Conway & Pleydell-Pearce, 2000), damage to neocortex may impair the semantic aspects of autobiographical memory, leaving the perceptual, event-specific information intact, just as is the case for anterograde memory (see Graham et al. 1999, 2000). In these respects, MTT and traditional consolidation theory are in agreement. Where they diverge is with regard to the autobiographical residue of semantic memory. Just as autobiographical memories have semantic components, so purportedly semantic memories may have autobiographical components associated with them which can influence performance on semantic tests. For example, we may not only know information about a famous person, such as that John Kennedy was an American President who was assassinated, or that Princess Diana was a member of the British Royal

family who was killed in a car accident, but we also have autobiographical memories associated with them, such as where we were and how we felt when we heard of their deaths (Westmacott & Moscovitch, 2003). When making ostensible semantic decisions about these people, such as fame judgments, or even reading their names, the episodic component influences performance. According to traditional consolidation theory, these autobiographical components of semantic memory, like the semantic components themselves, are mediated by neocortex once consolidation is complete. MTT, on the other hand, maintains that these autobiographical components continue to rely on the hippocampus for retention and retrieval.

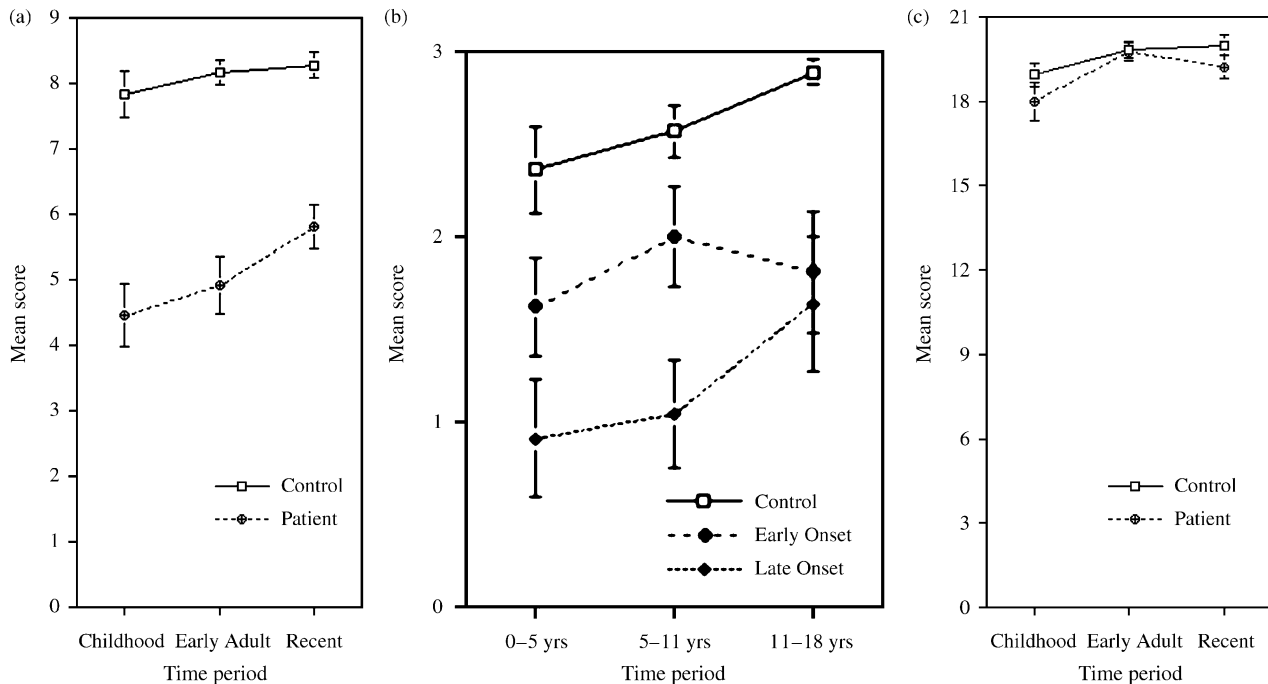
### **Allocentric spatial memory: is the hippocampus always necessary?**

MTT and the standard model also make different predictions regarding spatial memory. According to MTT, but not consolidation theory, re-experiencing detailed, event-specific spatial aspects of an autobiographical episode, or spatial-perceptual features contained within an environment that are incidental to navigating in it, requires the hippocampus no matter how long ago the memory was acquired. Consolidation theory predicts that all forms of allocentric spatial information, crucial for navigation in familiar environments, can be retained if the hippocampal lesion occurred after the information had been assimilated. As noted above, MTT can address this issue in two ways. First, it is possible that semantic allocentric information ultimately can be represented outside the hippocampus. Alternatively, if cognitive map theory is correct, all allocentric, spatial information will be lost no matter how long ago it was acquired, irrespective of whether or not it enables re-experiencing.

### **New evidence on neuroanatomical substrates of remote memory: comparison between MTT and the standard consolidation model**

#### **Autobiographical memory**

Evidence from people with focal lesions and dementia Since we last reviewed the literature in 1998 (Fujii et al. 2000), the evidence that has accumulated continues to favour MTT over the consolidation model, though it still is not conclusive (see Moscovitch et al. 2005). Using



**Fig. 3** Left panel: Autobiographical episodic memory performance. Mean scores on episodic components of the Autobiographical memory interview (AMI; Kopelman et al. 1989) for control ( $n = 22$ ) and patient ( $n = 25$ ) groups. The maximal score is 9 per time period. Vertical lines depict standard errors of the means. Middle panel: Autobiographical episodic memory performance during earliest time periods. Mean scores on episodic components of AMI for control ( $n = 22$ ), late seizure onset ( $n = 11$ ) and early seizure onset ( $n = 8$ ). Late seizure onset describes patients who reported first seizures after age 18; early seizure onset describes patients who reported first seizures before age 5. The maximum score is 3 per time period. Right panel: Personal semantic memory performance. Mean scores on semantic components of AMI for control ( $n = 22$ ) and patient ( $n = 25$ ) groups. The maximum score is 21 per time period. Vertical lines depict standard errors of the means. (From Viskontas et al. 2000).

the Autobiographical memory interview (AMI) (Kopelman et al. 1989), Viskontas et al. (2000) found that people with unilateral temporal lobe epilepsy or temporal lobectomy had poorer than normal memory for autobiographical events, even those dating to early childhood, but had normal memory for personal semantics (Fig. 3). Loss of autobiographical memory with no temporal gradient favouring the most remote memory (in fact, remote memories were remembered worse than recent ones) held even for people with late-onset seizures. Though lobectomy included lateral and anterior temporal structures, it is unlikely that memory loss was associated with these lesions since the deficit was comparable to that of people with epilepsy confined to the hippocampal region.

Similarly, Cipilotti et al. (2001) reported a retrograde memory loss that extended the entire lifetime, with no temporal gradient, in a patient with extensive late acquired lesions confined to the hippocampal region. Memory for public events was also impaired, but the test used may have had a strong episodic component as only events that had limited exposure were tested.

Because recollection of autobiographical episodes entails re-experiencing of events in rich detail, Moscovitch et al. (1999) devised new tests, based on research by Suengas & Johnson (1988), which assessed the amount of detail that was recovered better than did older tests, such as the AMI or the Galton–Crovitz–Schiffman (GCS) cue word tests (Crovitz & Schiffman, 1974). Whereas memories in these latter tests were scored on a three-point scale, which would assign an equal score of three to all memories that could be identified as to time and place and had some detail, the new scoring procedures credited each detail (much as in scoring of anterograde memory on logical stories of the WMS-R and WMS-III). This allowed one to distinguish among people whose memory varied in vividness. In addition, we instituted probing procedures to allow individuals with poor memory to reveal all that they may remember. In later versions, we also distinguished between different types of memory, particularly those which were specific (internal) to the remembered event (episodic) and those which were common to other memories (external or semantic; Levine et al. 2002).

Using the new scoring technique, Moscovitch et al. (1999) found that amnesic people whose memory of remote events fell in the normal range according to the three-point scoring system, recalled far fewer details according to the new scoring system. Admittedly, the people they tested did not have lesions confined to the hippocampal region, so that extra-hippocampal lesions may have contributed to their extensive retrograde amnesia.

Steinvorth et al. (2005) applied the new scoring method of Levine et al. (2002) to Scoville & Milner's patient, H.M., and to W.D., both of whom had lesions that were much more circumscribed and largely confined to the MTL. They, too, like the patients of Moscovitch et al., showed a retrograde amnesia for internal, episodic components of autobiographical events across their entire life, without a temporal gradient. As a control, they showed that on comparable tests of semantic memory for public events, their performance was much better, and showed the typical gradient, with the more remote memories being relatively spared.

Likewise, Gilboa et al. (submitted) applied similar techniques to study memory in A.D.F., an amnesic patient with small, bilateral lesions to the fornix, an output pathway of the hippocampus, and a small lesion in the left, basal forebrain region, which typically does not lead to extensive, lasting, memory loss. Like H.M., the patient's remote, autobiographical memory loss extended across his entire life without evidence of a temporal gradient, but personal semantic and generic memories were spared. This pattern resembled anterograde memory loss in patients with bilateral fornix lesions (Aggleton et al. 2000), who showed deficits in recollection but not familiarity. Importantly, A.D.F. also showed anterograde deficits in recollection and preserved familiarity, suggesting a common function for the hippocampus across anterograde and retrograde memory.

Mindful that our procedure depends on recall which may be biased by probing, and may involve reconstruction of details to which some patients may be more prone than others (Kapur et al. 2002), Gilboa et al. (submitted) devised recognition tests based on reports from people close to the patients. The tests focused either on episodic details or on generic, semantic information relevant to the event. A.D.F.'s performance on recognition resembled his performance on recall tests of autobiographical memory: he displayed poor performance on recognition of episodic details and

preserved recognition of semantic ones. By contrast, K.C., another patient with bilateral hippocampal lesions (see Rosenbaum et al. 2005) but with damage to other parts of the MTL and neocortex, performed also poorly on the semantic component. This corresponds to an extensive and ungraded retrograde amnesia for autobiographical episodic and semantic details in K.C. on the measure of Levine et al. (2002) (Rosenbaum et al. 2004b). Rosenbaum et al. also investigated whether the recovery of autobiographical details continues to rely on the hippocampus, or whether these memories depend on visual imagery or strategic retrieval of details, mediated by visual extrastriate (medial occipital) or prefrontal cortex, which also are damaged in K.C. However, performance was normal on visual imagery testing, and autobiographical memory did not benefit from a retrieval support manipulation, contrary to what would be expected if respective medial occipital or frontal lesions were responsible.

Together these studies present a very strong case in favour of MTT over the standard consolidation model. The only recent evidence favouring the standard model is supplied by Bayley et al. (2003), who report that amnesic patients with lesions confined to the MTL have intact, detailed autobiographical memories from the first third of their lives. They used the GCS cuing technique to elicit the memories, and probing was minimal, but they scored the memories using the procedure of Levine et al. (2002). The number of details they report for their controls (who do not differ from their amnesic people), however, is far lower than that reported by our controls: approximately 20 internal details to our 50. In fact, their controls score even lower than our amnesic people. Their findings suggest that the memories they elicited may not have been truly vivid even in their controls, a fact that is not surprising considering that they were asked to recall 36 memories from the first third of their lives to single word cues.

One criticism invoked by proponents of the standard model is that evidence from many single case studies is suspect because lesions often extend beyond the MTL to include lateral neocortex. Although we reviewed cases with extensive retrograde amnesia with lesions confined to MTL (see Fujii et al. 2000; Moscovitch et al. 2005; this paper), another approach is to conduct group studies to see if the extent of autobiographical and semantic memory loss correlates with the age of the memory, as the standard model predicts, or with the size of MTL lesion, as MTT predicts. The evidence

suggests that the location of extra-MTL cortical damage and subcortical damage also needs to be taken into account.

The relationship between the size of MTL lesions, loss of autobiographical memory and personal semantics, and age of memory was examined by Gilboa et al. (2005) in a group of people with mild to moderate Alzheimer's disease (AD) and by Kopelman et al. (2003) in people with focal lesions of various etiologies. Using MRI volumetry of 28 structures comprising the entire brain, and the multivariate analysis method of partial least squares (PLS), Gilboa et al. found a strong correlation between retrograde autobiographical memory, as measured by AMI, and the amount of remaining tissue in bilateral MTL, more on the right than the left, and in anterior lateral temporal cortex. The age of the memory had no effect on the correlation, and neither did personal semantics whose loss was correlated with another set of structures, such as anterior temporal, lateral temporal and prefrontal cortex but not MTL. Kopelman et al. also found extensive retrograde amnesia uncorrelated with age of memory, but also no correlation with MTL lesions in a group of patients with focal MTL lesions, though they did report a significant correlation with MTL lesion size in a group that also had diencephalic lesions.

Although neither study supports the standard model's prediction that age of memory is a determining factor of memory loss, it is not clear why the correlation with size of MTL lesion was not consistently found. To account for the differences between the two studies, Gilboa et al. (2005) suggested that combining different etiologies of focal lesion patients in the Kopelman et al. (2003) study may have obscured an association between MTL intactness as reflected by volume and memory functioning. For example, anoxia primarily affects the CA fields, and damage may or may not encroach on the subiculum. This would lead to relatively small volume loss, but the potential for large memory deficits. Indeed, this is precisely the way Kopelman et al. (2003) interpret the impressive 0.8 correlation between hippocampal volume and event memory in their diencephalic group. On the other hand, encephalitis causes extensive losses to MTL cortical regions and thus may lead to overall larger volume loss. However, depending on the extent and precise structures affected, memory loss may vary considerably.

Investigating remote memory in people with semantic dementia (SD) is also informative because neural

degeneration associated with SD affects primarily the anterior and lateral temporal cortex, typically on the left, leaving the MTL relatively spared (Mummery et al. 2000). If remote autobiographical memories are represented in neocortex, as the standard model predicts, then patients with SD should show impaired memory for remote events, but preserved memories for recent ones, a pattern opposite to that which the standard model predicts for amnesia. Using variations of the AMI and GCS procedures, this is exactly what Graham & Hodges (1997) reported. Westmacott et al. (2001), however, argued that this pattern is observed only because patients with SD do not have the verbal means necessary to comprehend the instructions, use the information as cues to retrieval, or express themselves adequately. Given nonverbal cues, such as family photos of particular events, and the opportunity to communicate by gestures, intonation, and so on, Westmacott et al.'s SD patient showed that remote autobiographical memory was relatively preserved, a finding corroborated by Moss et al. (2003), Ivanoiu et al. (2004) and Piolino et al. (2003). One of the patients of Graham et al., however, continued to be impaired in retrieving all memories except those from the last two years, even when tested using the methods of Westmacott et al. (Graham et al. 2003a).

The source of the discrepancy among the studies remains unknown. A likely possibility is that the extent and locus of degeneration differs among patients, but whether the differences lie in MTL, anterior and lateral temporal lobes, or even pre-frontal cortex (PFC), has yet to be determined (Nestor et al. 2002). Correlating size of brain structure with memory in SD, as Gilboa et al. (2005) did in AD patients, may help resolve the debate.

Though the evidence generally supports MTT, a number of issues remain unresolved and await future studies that pay equal attention to lesion size and location, and to the methods used to elicit memories and score them. Because patients with circumscribed lesions restricted only to some parts of the HC/MTL are rare, and often there is disagreement about the purity and extent of their lesions, and because group studies are not immune to these problems, many investigators have turned to functional neuroimaging studies of healthy people to address some of these issues. Though not without problems of its own (see Maguire, 2001a), functional neuroimaging studies can provide valuable information about the functional neuroanatomy of

remote memory, and appears to converge on conclusions obtained from patient studies.

#### Evidence from functional neuroimaging

The standard model and MTT make different predictions about hippocampal activation during retrieval of recent and remote autobiographical memories of specific events. According to the standard model, hippocampal activation should be evident for recent but not for remote memories, whereas the reverse should occur for neocortical activation. By contrast, MTT predicts equivalent HPC activation for recent and remote memories as long as they are vivid and detailed. Using event-related functional magnetic resonance imaging (efMRI) designs, Ryan et al. (2001) presented cues during scanning which were derived from prescan interviews about autobiographical events. They found bilateral hippocampal activation associated with re-experiencing those events in the scanner. Similarly, Maguire and her collaborators (Maguire, 2001a; Maguire et al. 2001; Maguire & Frith, 2003), found mostly left-sided activation while participants made recognition judgments to statements referring to autobiographical events in comparison to control conditions which included statements about general personal events or public events, all based on prescan interviews. In one study, Maguire et al. (2001a) directly tested whether hippocampal activation was modulated by the age of the memories, and found no evidence for this claim of the standard consolidation theory. In all the other studies, hippocampal activation was equivalent for recent and remote memories, thereby favouring MTT over the standard model. Piolino et al. (2004) reported similar findings and conclusions using positron emission tomography (PET; cf. Conway et al. 1999 for similar PET results).

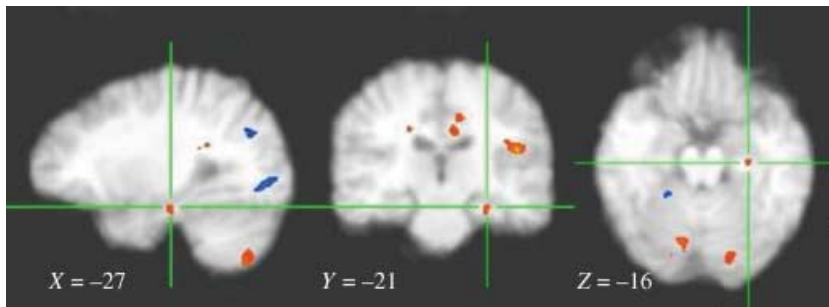
There were two possible confounds in these studies. One concerned item selection. Because all the events studied were based on prescan interviews with the participants, it is difficult to know whether truly remote memories were retrieved in the scanner, or only memories of the interviews. If the latter were the case, similar hippocampal activation would have been observed to statements regarding personal semantics and public events, which was not the case (Maguire, 2001a). To control for this possible confound further, Ryan et al. (2001) also used items selected by a close relative or friend, whereas Maguire et al. (2001) tested the

developmental hippocampal amnesic, Jon, for the few events he could recollect from his remote past, even though he had no memory for the prescan interview. In both cases, greater hippocampal activation – that did not vary with time – was found for autobiographical than for other events.

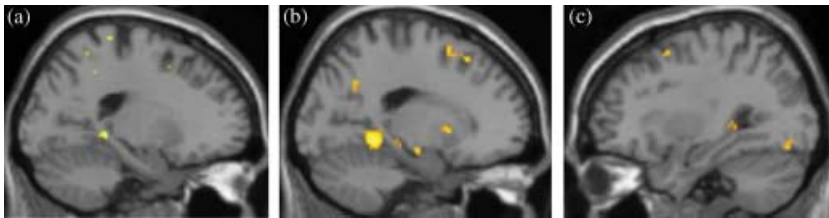
The second possible confound is that hippocampal activation that is observed reflects *re-encoding* of memories as they are retrieved in the scanner, rather than activation associated with the initial retrieval itself. Sensitive to this criticism, Gilboa et al. (2004) had a person close to the participant select family photos which the participant had not viewed recently and which were shown only in the scanner. The photos were from four or five time periods dating from early childhood (at least 20 years ago) to the last six months. To control for the effect of re-encoding, the participant also was presented with photos from a stranger's family album which were matched as much as possible in style and content to the participant's own photos.

On viewing 'self' photos in the scanner, the participant had to re-experience the depicted event in as much detail as possible; in viewing the 'other' photo, the participant had to imagine in equivalent detail a scenario concerning the event depicted in the unfamiliar photo. If re-encoding were a factor, no difference in hippocampal activation should be observed between the 'self' and 'other' conditions, since both types of material are being encoded, but only one requires retrieval of old memories. Gilboa et al. (2004) found that activation was greater for old, 'self' memories than for novel, imagined 'other' material in a number of regions, including the left hippocampal complex (see also Maguire et al. 2001a; Addis et al. 2004a), thereby arguing against the re-encoding interpretation.

Of equal interest was the finding, consistent with MTT but not with the standard model, that left hippocampal activation was related not to the age of the memory, but rather to its richness, as determined by postscan vividness ratings for all of the memories, and by descriptions for a subset of them from each time period (see Fig. 4). Because Gilboa et al. (2004) found that, on average, recent memories are more vivid and detailed than remote memories, it is likely that these variables, rather than age, account for the temporally graded hippocampal activation reported in other studies (Niki & Luo, 2002; Eustache et al. 2003; Maguire & Frith, 2003; Piefke et al. 2003).



**Fig. 4** Activation from vividly (red) vs nonvividly (blue) recalled events. The cross hairs on the images are centred at activations within the spherical search regions of the hippocampus which have the following Talairach & Tournoux (1988) co-ordinates: Reading from left to right,  $x = -27$ ,  $y = -21$ ,  $z = -16$ . Radiological coordinates are used so that left/right is reversed. (From Gilboa et al. 2004.)



**Fig. 5** Activity in the medial temporal lobes is parametrically modulated by the level of recollective qualities of autobiographical memories, independent of their recency. Regions included the left hippocampus, modulated by the level of detail (a) and personal significance (b); and the right hippocampus, by the personal significance of the memories (c).

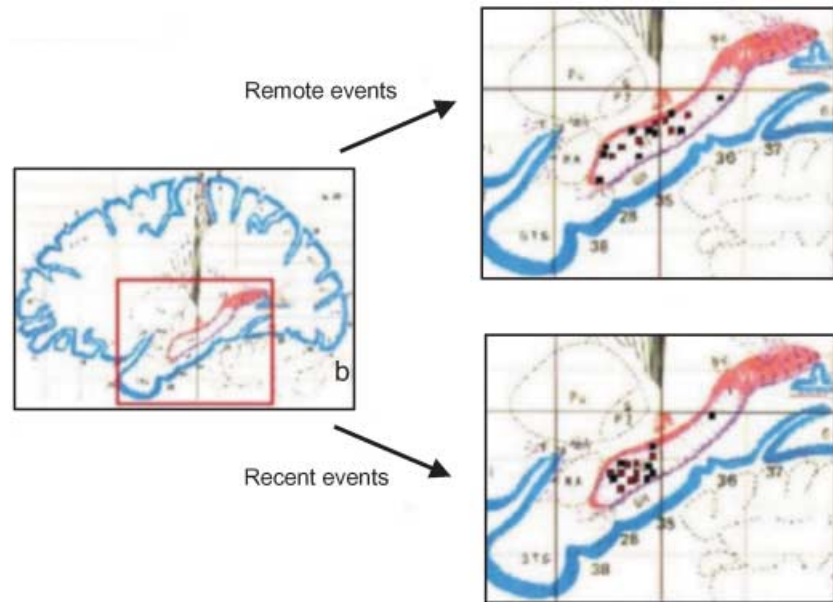
This interpretation was confirmed in a parallel fMRI study by Addis et al. (2004a) designed to determine whether recency or recollective qualities, such as detail, emotionality, and personal significance, modulate hippocampal activity during retrieval of autobiographical memories of unique or repeated events. During scanning, participants retrieved temporally specific autobiographical memories and general, repeated autobiographical memories, and rated each for level of detail, emotionality, or personal significance. Addis et al. found that each of these qualities influenced medial temporal activation during the retrieval of either specific or repeated autobiographical memories (see Fig. 5). Recency independently modulated hippocampal activity, but its effects were reduced or eliminated when the other factors were included as covariates. Conversely, robust modulation of hippocampal activation was observed for the three qualities even when recency was included as a covariate (see also Graham et al. 2003b).

Together, the studies by Gilboa et al. and by Addis et al. show that quality of the recollective experience – its vividness, emotionality and personal significance – is the determining factor in activating the hippocampus; memories of personal facts or public events, or the age of the memory, have little effect on hippocampal activation. It may still be possible, as some proponents of the consolidation model have argued (Shimamura, 2002), that the hippocampus is activated during any retrieval search for autobiographical memories, but that its activation may not be necessary for successful

retrieval of remote memories; only lesion studies can prove that. Such a proposal, however, would be hard put to explain the specificity of HPC activation noted in the above studies, and its relation to the success of retrieving vivid autobiographical memories.

The results of neuroimaging studies are consistent with the model of Aggleton & Brown (1999) and with recent lesion and neuroimaging evidence of anterograde memory: the hippocampus is engaged by recollection, an index of autobiographical re-experiencing (Tulving, 1985) of recently acquired memories for words and faces in the laboratory, and not simply by familiarity with them. Thus, a number of studies have shown that recollection was disproportionately impaired following lesions that included the hippocampus, whereas familiarity was relatively spared (Holdstock et al. 2002a,b; D. Moscovitch & McAndrews, 2002; Yonelinas et al. 2002; Mayes et al. 2003, 2004). Likewise, neuroimaging studies have shown that the hippocampus was activated preferentially during recognition of items that were recollected as compared to those which were only considered familiar (Eldridge et al. 2000; Dolcos et al. 2002; Davachi et al. 2003). Our own preliminary findings (Caza et al. 2004) have shown that even for recognition of newly learned associations, those which are accompanied by recollection show the greatest hippocampal activation. This finding emphasizes that recollective experience, rather than simply the retention and recovery of newly formed associations, is the salient factor in hippocampal memory processes.

**Fig. 6** Schematic renderings of remote and recent activations. Each point corresponds to a statistically significant activation from within the left hippocampus in either remote (top;  $n = 18$ ) or recent (bottom;  $n = 16$ ) conditions. Red and black squares represent activations at a significance level of  $P < 0.001$  and  $P < 0.01$  uncorrected, respectively. Activations are shown on a single sagittal plane taken from the Talairach & Tournoux (1988) atlas (25 mm lateral to the midline). Overlapping activations were offset slightly in the recent condition. Differences in the lateral displacement of the activations from the midline (along the x-axis of the Talairach atlas) are not represented in the figure. The lateral and vertical dimensions did not show any obvious systematic variability and therefore are not considered as a part of the overall pattern of interest. (From Gilboa et al. 2004.)



Gilboa et al. (2004) also found that foci of activation in the hippocampus were distributed differently for recent and remote memories, with the former clustered in the anterior region of the hippocampus and the latter distributed along its rostral–caudal axis (see Fig. 6). It is not yet clear why this pattern should occur. If each retrieval leads to the formation of new traces within the MTL, as MTT predicts, then remote memories should be more widely distributed than recent memories in MTL, and may survive minimal damage to the MTL.

Other possible interpretations of this pattern of activation are that remote memories, particularly those dating to childhood and adolescence, may be encoded differently from more recent, adult memories, or that recent memories may retain their emotional strength more than remote ones. With respect to the latter possibility, Dolcos et al. (2002) reported that emotional memories activated the anterior hippocampus more than nonemotional ones, although in their study emotionality interacted with recollection, and all their memories were recent by our standards.

#### Extra-hippocampal contributions to autobiographical memory: lesions and neuroimaging

Although the focus has been on the hippocampus and related MTL structures, other brain regions are implicated in retrieval of autobiographical memory, some of which display a pattern of activation sensitive to the

age of the memory. As we noted earlier, there is a memory retrieval network reported by Maguire and others (Conway et al. 1999; Maguire & Mummery, 1999; Maguire, 2001a; Maguire et al. 2001; Ryan et al. 2001; Piefke et al. 2003; Addis et al. 2004a,b) that consists primarily of left-lateralized structures when memory for all types of remote events (autobiographical events and facts, public events, general knowledge) are compared with nonmemory control tasks (see Maguire, 2001a). In addition to the left hippocampus, the regions included in the network are the left medial frontal cortex, left temporal pole, left antero-lateral middle temporal gyrus, left parahippocampal cortex, retrosplenial/posterior cingulate cortex, precuneus (medial occipital), left temporoparietal junction, right temporal pole, right posterior cerebellum and the thalamus. Because the specific contribution of these regions to each type of memory was not examined systematically (but see Addis et al. 2004a,b), we can only speculate about their function based on information gained from other studies. Only some of the regions will be considered.

#### Prefrontal cortex

When Maguire (Maguire, Henson et al. 2001a) compared autobiographical events to any of the other types of memory, only the left hippocampus and medial frontal cortex were activated more during autobiographical memory retrieval, a finding consistent with the observation of Gilboa (2004b) that the latter

region is preferentially activated during retrieval of autobiographical memory in comparison to other types of episodic memory. We know that damage to this region is associated with temporally extensive retrograde amnesia and confabulation (Gilboa & Moscovitch, 2002), suggesting that it may be a crucial area for automatically monitoring the retrieved memories (Moscovitch & Winocur, 2002). In addition, this region of prefrontal cortex also is activated during self-reference, which is a component of autobiographical memory (Craik et al. 1999).

In another event-related fMRI study, Maguire, Henson et al. (2001) found a region in right ventrolateral prefrontal cortex that was modulated by the age of the autobiographical memory, showing increased activation to the more recent memories. Activation of this region has been associated with specification of retrieval cues in many neuroimaging studies of episodic memory (Fletcher & Henson, 2001). Maguire et al. (2001) speculate that activation in ventrolateral cortex reflects the degree of integration of the memory trace with the contextual information that can provide retrieval cues. The more recent the memory, the more likely it is to be contextually rich and the more active the integration. Whatever the true underlying cause of the activation, the age-related pattern is opposite the one predicted by the standard model for neocortex (but see Maguire & Frith, 2003).

The pattern of activation observed in prefrontal cortex is consistent with its role as a *working-with-memory* structure that is involved in strategic aspects of retrieval such as establishing a retrieval mode and goals, initiating and guiding search, and monitoring and verifying the memories that have been retrieved (Moscovitch, 1992; Moscovitch & Winocur, 2002). Gilboa's review of the literature (Gilboa, 2004b), however, suggests that some subregions in prefrontal cortex, particularly parts of the frontal pole and ventromedial aspects, may be activated preferentially during retrieval of autobiographical as compared to other types of memory. Lesions to the lateral and polar aspects of prefrontal cortex are associated with deficits in autobiographical memory retrieval, but as would be expected of these general-purpose, executive structures, they operate equally on recent and remote memories (Kopelman et al. 1999, 2003). Greater activation may be evident for those memories that are difficult to retrieve and, consequently, greater loss of such memories may occur following damage to those structures.

#### *Medial occipital and inferotemporal cortex*

In Gilboa et al. (2004), retrieval of context-rich memories was associated with activity in lingual, fusiform and precuneus gyri independently of their age (see also Ryan et al. 2001). The precuneus often is implicated in imagery and spatial processing in the context of episodic memory. Bilateral activation in the lingual and fusiform gyri (BA 19/37) may be related to the complex visual stimuli (photos) and the extended period for re-experiencing used in their study, which likely induced more sensory perceptual memory-related activation than the verbal materials used in previous studies. Similar results are found, however, even in studies not using photos as memory cues. Addis et al. (2004b), who used memory titles as cues, found that specific autobiographical memories, rated as more detailed than repeated autobiographical events, were differentially associated with activity in the left precuneus, left superior parietal lobule and right cuneus (but see Graham et al. 2003b).

Neuroimaging studies showing activation of posterior neocortex and inferotemporal regions during retrieval of autobiographical memory are consistent with reports by Ogden (1993) and others that damage to these structures, which is associated with visual, object agnosia and loss of imagery, can also produce a profound, temporally extensive retrograde amnesia for autobiographical events (see reviews by Rubin & Greenberg, 1998 and Greenberg & Rubin, 2003). Because re-experiencing autobiographical episodes is accompanied more by visual imagery than by any other kind of perceptual information, it has been speculated that damage to these structures destroys the representations forming the crucial portion of the content of autobiographical memories.

#### *Retrosplenial/posterior cingulate*

Activation in this region is consistently reported in imaging studies of autobiographical memory and often is greater than that in any other region (Maguire, 2001a,b). Damage to this region is known to cause severe amnesia (Bowers et al. 1988; Heilman et al. 1990), but likely of limited duration. In Gilboa et al. (2004), direct comparison of events that were re-experienced and those that were not yielded activation in the precuneus/posterior cingulate, but not the retrosplenial cortex proper (Vogt et al. 2001), suggesting that these regions should not be treated as part of the same functional system. As we noted, the precuneus has been labelled the 'mind's eye' (Fletcher et al. 1995)



and its involvement in imagery and episodic memory is well-established (Cabeza & Nyberg, 2000). The posterior cingulate is involved in topokinetic and topographical processing, including retrieval of spatial context and assessment of retrieved spatial representations (Burgess et al. 2001; Maguire, 2001b; Vogt et al. 2001; Rosenbaum et al. 2004a), and thus may be performing a similar function in the visuospatial domain.

The retrosplenial cortex (a region within the bank of the callosal sulcus; Vogt et al. 2001) was significantly more active in Gilboa et al.'s study for recent memories than for remote memories, even in the comparison that included only the remote memories that were vividly re-experienced. These findings are consistent with the hypothesis that this structure is needed to activate, integrate, and construct generic visual representations in posterior neocortex (Conway & Pleydell-Pearce, 2000), which may be more plentiful for recent than for remote memories. Highly detailed generic and semantic information may support or provide a framework for the construction of specific episodic memories (Burgess & Shallice, 1996). Such a function contrasts with that of the posterior cingulate/precuneus, which is apparently directly associated with retrieval of vivid specific memories, displaying a similar pattern of activation as the hippocampus.

### Overview and summary

Taken together, the evidence from the lesion and neuroimaging studies favours MTT in that the HC/MTL is needed for the retrieval of autobiographical memories independent of their age. The evidence, however, is not conclusive. The temporal gradient observed in some of the lesion studies may be related either to stronger and more distributed traces in the hippocampus, making them more resilient than recent memories to partial damage of the hippocampus, or to the greater *semanticization* of remote, as compared to recent, memories, making the former less dependent on the hippocampus. The neuroimaging evidence is consistent with both of these alternatives. Remote memories have been found to be more dispersed across the rostrocaudal extent of the hippocampus than recent memories which are clustered in its anterior portion. In addition, hippocampal activation is related to the recollective qualities of autobiographical memory, such as details, vividness, emotion, and personal significance rather than the age of the memory per se. Because

these factors can covary with age, one may erroneously interpret the changes in hippocampal activation with age as suggesting that its involvement in autobiographical memory is temporally limited. On the contrary, when all factors are taken into account, it has been shown that the age of the memory has no influence on hippocampal activation. Thus, the studies support MTT over the standard model.

Nonetheless, MTT, as initially formulated (Nadel & Moscovitch, 1997), would need to be modified to account for some of the more recent findings. According to MTT's initial formulation, both the severity and extent of retrograde amnesia for episodic memory should be related to the size of the MTL lesions. However, the more recent evidence reported since 1998, and based on more sensitive methods of assessing episodic memory, suggests that severity of retrograde amnesia is related more closely to MTL damage or atrophy than is temporal extent of the amnesia. If confirmed, such findings would necessitate a reconsideration of the role that multiple traces play in the representation of remote memories in the hippocampus. In addition, the model will have to be modified to account for the different contribution of the various regions of MTL to different aspects of remote memory, just as theories of anterograde memory have.

Regardless of their relevance to MTT and consolidation theory, neuroimaging studies have shown that the hippocampus is at the hub of a network of neocortical and limbic structures whose neurons it binds into a memory trace. The extra-hippocampal structures – usually posterior neocortical, and lateral and anterior temporal, structures – that contribute to the memory trace are activated to the extent that the information they carry is implicated in that particular memory trace. During retrieval, the prefrontal cortex acts as a working-with-memory structure that initiates and guides retrieval from the HC/MTL and monitors its output. Evidence from neuroimaging and lesion studies suggest that some structures in posterior neocortex, such as retrosplenial, inferotemporal and extrastriate cortex, and in prefrontal cortex, such as its ventromedial and polar aspects, have a privileged role in retrieval of remote autobiographical memories.

### Semantic memory

In contrast to the discrepancy among studies and the controversy surrounding episodic memory, there is general

agreement regarding semantic memory. According to both the standard model and MTT, remote memories of the gist of events, of personal semantics, of public knowledge of people and events, and of vocabulary, are not dependent on the continuing function of the HC/MTL. [Looked at more broadly, semantic memory encompasses all the general knowledge one has about the world, and as such, likely implicates a large network of structures in the neocortex, including the prefrontal cortex, inferior and superior temporal cortex, the junction between occipital, temporal, and parietal cortex, and possible regions of premotor cortex. Because we cannot deal with all these in this paper, we refer the reader to excellent reviews by Martin & Chao (2001), Wagner et al. (2001), Thompson-Schill (2003), and McClelland & Rogers (2003).] Instead, the HC/MTL is needed only temporarily, until the memory is represented permanently in neocortical structures specialized in processing the acquired information and capable of being modified while doing so. At first glance, semantic memory therefore behaves in a manner consistent both with the standard model and with MTT. Examined more carefully, differences between the two views appear even here.

#### Lesion studies

The evidence from lesions studies bears out predictions from both models. Damage restricted to the hippocampal complex, or the fornix (Gilboa et al. submitted), leads to a temporally graded retrograde amnesia for words, faces and names of famous people, public events and even personal semantic knowledge, that typically does not extend for longer than 10 years (Manns et al. 2003; Moscovitch et al. 2005; but see Sanders & Warrington, 1971; Cipilotti et al. 2001), after which performance is normal and believed to be dependent only on neocortex. In addition, the size of the MTL lesions is not correlated with performance on tests of personal semantics in people with focal lesions (Kopelman et al. 2003) or with dementia of the Alzheimer type (Gilboa et al. 2005).

Consistent with this interpretation, it is only damage to extra-hippocampal structures in the lateral and anterior temporal lobes, particularly on the left, that leads to much more severe and temporally extensive loss of remote memories for facts, events and people. Loss of semantic memory, including vocabulary and personal semantics, is associated with damage to posterior neocortical structures, particularly the lateral

aspects of the temporal lobe, while loss of names and knowledge of famous people, with damage to the left temporal pole (Eslinger, 1998). Such loss is evident in many patients with dementia and neocortical degeneration, such as people with AD, where the severity and temporal extent of the deficit increases with disease progression (Westmacott et al. 2004a; Gilboa et al. 2005).

Semantic memory loss is most revealing in people with SD whose medial temporal lobes are relatively spared (Graham & Hodges, 1997; Snowden et al. 1994, 1996). They show a reverse temporal gradient, or step function, with recent semantic memories being preserved and remote ones impaired. Though the reverse temporal pattern has been observed in some patients for both episodic and semantic memory (Graham, 1999), in other patients, it has been noted only for semantic memory, with episodic, autobiographical memories being spared, presumably because they are dependent on the medial temporal lobes (Westmacott et al. 2001; Westmacott & Moscovitch, 2002; Moss et al. 2003). What accounts for the individual differences in the patterns of preservation and loss among SD patients has yet to be determined (see Graham et al. 2000, 2003a; Westmacott et al. 2001; Moss et al. 2003).

The MTT, unlike the standard model, posits that the hippocampus plays only a supporting role, but not a crucial one, in forming semantic memories, at least early in development when conceptual knowledge is acquired quickly and in large amounts. Recent evidence from studies of children whose hippocampi were damaged at birth or shortly thereafter would seem to support this view. Vargha-Khadem and her collaborators (Vargha-Khadem et al. 1997; Gadian et al. 2000) found that these children acquired sufficient general knowledge (semantic memories) to complete high school even though their memory for autobiographical episodes was impaired (but see Squire & Zola, 1998 for counter-arguments). Similar sparing of semantic, compared to autobiographical, memory in adults has also been reported in adults with hippocampal lesions (Kitchener et al. 1998; Van der Linden et al. 2001; Westmacott & Moscovitch, 2001, 2002; O'Kane et al. 2004; Skotko et al. 2004; but see Kitchener & Squire, 2000).

Proponents of the standard model, however, attribute the relative sparing of semantic memory, and its more rapid consolidation, to repetition or number of presentations (Squire & Zola, 1998). Episodic memories are based on events that occur only once, whereas semantic memories are based on repeated presentations of

the relevant information. Semantic memories, therefore, can be retained better and consolidated sooner than episodic memories, and, therefore, are more resilient to the effects of hippocampal lesions at both acquisition, retention and retrieval. Whether it is these factors alone, or also differences in the nature of semantic and episodic representations as MTT asserts, remains to be determined.

#### Neuroimaging studies

The neuroimaging evidence is less consistent and based on few studies. Some report no hippocampal activation; other report hippocampal activation without a gradient for personal semantics, knowledge of public events (Maguire et al. 2001) and famous faces (Kapur et al. 1995; Leveroni et al. 2000; Douville et al. 2005) still other report temporally graded activation in entorhinal cortex to famous faces (Haist et al. 2001). The source of the discrepancy is difficult to determine. One possibility is that some semantic memories may be associated with an episodic component which influences the type of activation that is observed. We discuss this possibility in the next section.

#### Alternative views of preservation of remote semantic memory: the standard model and MTT

Although the standard model and MTT make similar predictions regarding temporal gradients and neural representations for semantic memory, their explanations of the underlying causes are different. According to the standard model, the semantic memory that is held temporarily in the HC/MTL is identical to the memory that is stored permanently in neocortex. Indeed, some believe that prolonged consolidation effects a transfer of the same memory from one location to another (see Kandel, 2001, p. 1038) or strengthens the neocortical traces which initially were bound together by the hippocampus, a process that may be supplemented by repetition of the semantic information. MTT, on the other hand, asserts that information related to semantic memory, whose representation is dependent temporarily on the HC/MTL, differs in important ways from the semantic information represented permanently in neocortex. The former retains its episodic flavour, such that the semantic content is tied to the spatio-temporal (autobiographical) context in which it was acquired. The latter is stripped of its

episodic context and retains only the semantic core. By the MTT view, prolonged consolidation refers to the establishment of a semantic trace in neocortex that can survive on its own, but it does not entail the loss of the related episodic trace mediated by the HC/MTL, nor is it identical to it (see McClelland et al. 1995 for a computational model that argues for the necessity of two distinct memory systems and how the episodic contributes to the semantic, and Murre et al. 2001 for review of models of retrograde amnesia).

According to MTT, the two types of semantic memories can coexist, so that a person can have both an episodic and semantic representation of the same event, object or fact, one dependent only on neocortex, and one also relying on the HC/MTL. The two can become functionally dissociable following brain damage to the structures that mediate each type. The evidence from people with SD and medial temporal lobe amnesia supports this interpretation. Having lost the neocortical, semantic representation, people with SD rely on medial temporal representations to identify objects, people, places and facts. Thus, they will recognize an object or person that has autobiographical significance for them (their own vase or kettle, the names of people with whom they've interacted or about whom they have a cherished memory) but not the same type of objects which are not their own (e.g. another person's vase or kettle; Snowden et al. 1994, 1996; Graham et al. 1999) or people who are equally famous but not linked to an autobiographical memory. Conversely, amnesic people with medial temporal damage will recognize objects and individuals regardless of their autobiographical significance, but not be able to conjure an autobiographical event related to them (Westmacott et al. 2001; Westmacott & Moscovitch, 2003; Westmacott et al. 2004b). It should be noted, however, that the detailed episodic trace may also fade in normal people, as most such memories do, unless they are rehearsed, leaving only the general, semantic memory behind.

The separation of the two sources of semantic memory is illustrated best in the studies of Westmacott et al. (2004a,b) on episodic and semantic memory for famous names. In a first experiment, a large sample of people rated names according to familiarity, knowledge, and autobiographical significance. For example, two people, say Queen Elizabeth II and Princess Diana, could be equally familiar, but one of them evokes an autobiographical memory (we remember when we heard of Princess Diana's fatal car crash), and the other does not.

After collecting such data from a large sample of people, two sets of 25 famous names were created, matched for familiarity and knowledge, but the names in one set were high in autobiographical significance and the names in the other set were low. Because the sets were chosen to reflect the high agreement in the general population about the names, they could then be used in subsequent studies on a different group of people.

In this second study, new participants were shown these names and asked to judge whether they were famous, or to read them as quickly as possible. Their accuracy and latency to do so was measured. Although these tasks ostensibly were concerned with semantic memory, performance was strongly influenced by autobiographical significance: latencies were much shorter to names high in autobiographical significance than to those low in autobiographical significance. What is interesting is that the advantage for the autobiographically significant names was eliminated in people with focal MTL lesions and in people with AD with MTL degeneration. By contrast, in two people with SD, who presumably had neocortical degeneration but whose MTL was relatively spared, the advantage for names with autobiographical significance was relatively preserved, and possibly enhanced, consistent with the idea that their semantic memory is impaired, and what knowledge they have of the world is based primarily on their episodic memory (Snowden et al. 1996; Snowden & Neary, 2002).

These studies suggest that the picture regarding semantic memory, when examined closely, may be as complex as that for episodic, autobiographical memory. Tests of either type of memory are not pure, but rather consist of both episodic and semantic elements which need to be distinguished from each other, and separated, if headway is to be made in understanding the neural substrates that mediate them.

This point is highlighted in the study of Addis et al. (2004b) of memory for repeated autobiographical events, such as holiday dinners or vacations at a family home, or single episodes, such as a vacation to a friend's home and a birthday dinner at a restaurant. Memories of repeated events have a generic structure to them which makes them similar to personal semantic knowledge, yet they carry autobiographical significance and detailed perceptual information, which makes them akin to autobiographical memories. Not surprisingly, Addis et al. noted activation for repeated events in structures associated with semantic memory,

such as the lateral inferotemporal and prefrontal cortices, as well in the hippocampus and other MTL regions, which are associated with autobiographical memory.

### Overview and summary

Taken together, the results from the lesion and neuroimaging studies speak to a fundamental distinction between remote memory for episodic and semantic information. Whereas detailed memory for autobiographical episodes is dependent on the medial temporal lobes for as long as the memory exists, memory for semantic information benefits from the MTL (hippocampus and peri-hippocampal cortex) for only a limited time, and can be acquired, slowly and with difficulty, without it. Thus, unlike episodic memory, semantic memory for public events, people, vocabulary and even facts about oneself (personal semantics) shows only a temporally limited retrograde amnesia, lasting about 10 years, following HC/MTL lesions in humans. Semantic memory is mediated by a network of neocortical structures, including lateral and anterior temporal lobes, and inferior frontal cortex, usually on the left.

These findings are consistent with MTT and the standard model. In comparison to the standard model, however, MTT argues that the 'semantic' memory that benefits from hippocampal involvement during the initial period is not identical to the one that is retained after that initial vulnerable period has passed. *What appears to be memory consolidation really is memory transformation*, from a semantic memory embedded in a rich context to one in which the context has been lost, or one that becomes impoverished so that only the semantic core remains. Evidence from humans – and rats (Rosenbaum et al. 2001) – supports this idea, and also demonstrates that the two types of 'semantic' memories can coexist and contribute to performance in normal people and rats.

### Spatial memory

#### Lesion studies

An important distinction in studies of spatial memory is between routes and maps. 'Route knowledge describes the information that encodes a sequential record of steps that lead from a starting point, through landmarks, and finally to a destination' (Aguirre et al. 1996; p. 1614). Route learning is based initially on coordinates

in an egocentric frame of reference, coupling landmarks to direction with reference to the self (e.g. 'turn left at the store'; Byrne, 1982). Thus, spatial representation in terms of routes is inflexible in that changes in landmarks or detours lead to disorientation. Maps, on the other hand, represent space in terms of allocentric coordinates that preserve the spatial relations of landmarks to one another. As a result, maps are flexible representations that do not depend on any single landmark or route to navigate from one place to another (cf. O'Keefe & Nadel, 1978).

Determining whether retrograde amnesia for different types of spatial memory is temporally graded or temporally extensive is of great relevance to theories of spatial memory. According to a long-standing spatial theory of hippocampal function, the hippocampus is considered crucial for maintaining and operating on cognitive maps necessary for navigation, whether the maps are old or newly formed (O'Keefe & Nadel, 1978; see Burgess et al. 2002 for an updated version). Spatial memory and navigation therefore should not survive hippocampal damage regardless of whether the memories are recent or remote.

Consistent with cognitive map theory, the role of the hippocampus in acquiring spatial memory in humans and in nonhuman organisms is beyond dispute (Eichenbaum & Cohen, 2001; Burgess et al. 2002), though the interpretation of the evidence has been vigorously debated for years (Eichenbaum, 2001; Eichenbaum & Cohen, 2001). What is less clear is whether the hippocampus is needed for memory and navigation of well-learned environments with which the individual had been familiar for years. There are numerous cases in the neurological literature of patients with deficits in spatial memory and navigation of familiar environments, but the lesions associated with such deficits rarely, if ever, implicate the hippocampus. In fact, we know of no reported case of impaired navigation in people with damage restricted to the medial temporal lobe that does not include the parahippocampal gyrus, though it is possible that such cases exist but have not been reported. Instead, the areas most implicated are the parietal lobe, the parahippocampal gyrus, and the posterior cingulate or retrosplenial cortex (Aguirre & D'Esposito, 1999).

Two recent studies examined systematically the remote spatial memory of two patients, K.C. and E.P., who have extensive bilateral damage to the hippocampus and related MTL structure (Teng & Squire, 1999; Rosenbaum et al. 2000, 2001; but see Corkin, 2002).

Though the patients were incapable of new spatial learning when tested on either artificial table-top or natural, large scale environments (a new neighbourhood or building), they performed well on a wide range of spatial-topographical measures based on a large-scale, natural environment learned long ago, even if it had not been experienced in decades (E.P.). In the case of K.C., he could navigate unaided in his old neighbourhood. Their intact performance on a variety of tests of spatial memory, in line with the previous neurological literature, suggests that structures other than the hippocampus mediate performance even on those tests that are allocentric. For both patients, the tests included (see Rosenbaum et al. 2000, appendix 1) (1) sketch mapping, (2) vector mapping, and (3) blocked-route problem-solving, the latter two being considered paradigmatic tests of cognitive map representation. In addition, K.C. performed normally on tests of (4) distance judgments, (5) proximity judgments, (6) sequencing landmarks along routes, and (7) recognizing gross features on world maps (i.e. continents, countries, oceans). He was severely impaired, however, in recognizing and identifying all but the major neighbourhood landmarks and in locating smaller features on world maps (i.e. cities). On the basis of these findings, Rosenbaum et al. (2000) concluded that what is retained after hippocampal damage is a skeletal or schematic spatial representation of the neighbourhood which is adequate for navigation but not for detailed re-experiencing of the environment in all its richness. A similar pattern of results was found by Gilboa et al. (in preparation) in a patient with bilateral lesions of the fornix. As we noted earlier, these schematic cognitive maps may be considered spatial analogues of semantic memory, with the detailed, perceptual-spatial representations being analogous to autobiographical or episodic memory. Consistent with this idea, the schematic spatial representations of familiar environments seem not to be dependent on the hippocampus, but perceptually detailed representations are.

These findings suggest that schematic representations of topography needed for navigation are dependent on extra-hippocampal structures that have been identified previously in people with topographic amnesia and agnosia and deficits in navigation (for reviews, see De Renzi, 1982; Farrell, 1996; Barrash, 1998; Aguirre & D'Esposito, 1999). These include the posterior parietal lobe, the parahippocampal gyrus, and the retrosplenial/posterior cingulate cortex, each of which performs

a particular function. The *posterior parietal lobe* is necessary for representing spatial information in terms of egocentric coordinates that allow for accurate reaching toward objects, movement with respect to landmarks in the environment (Farrell, 1996; Milner & Goodale, 1995) and imagining scenes from an egocentric perspective (Bisiach et al. 1993; Burgess et al. 2001, 2002). The *retrosplenial and/or posterior cingulate cortex*, on the other hand, is believed to code information about headings in allocentric space (Takahashi et al. 1997; Maguire, 2001b). A region in the *inferior temporal lobe*, around the anterior part of the lingual sulcus and posterior part of the *parahippocampal gyrus*, is crucial for identification of salient landmarks, such as buildings (Whiteley & Warrington, 1978; Incisa della Rocchetta et al. 1996; Aguirre & D'Esposito, 1999; Epstein et al. 1999, 2003) or encoding new landmarks as indicated by activation of this area when new houses are viewed (e.g. Haxby et al. 2000). Damage restricted to the parahippocampal gyrus impairs acquisition of new landmarks, but has little effect on remote memory for familiar landmarks (Habib & Sirigu, 1987). One view of the function of the parahippocampal gyrus is that it is crucial for coding visual-topographic information (Epstein & Kanwisher, 1998) and the other is that it is crucial for co-ordinating information that constitutes allocentric cognitive maps (Aguirre & D'Esposito, 1999; Epstein et al. 1999, 2003; Burgess et al. 2002). Consequently, by either view, individuals with right parahippocampal lesions are disoriented in new locations but not in familiar ones, and have difficulty learning locations based on new, allocentric spatial configurations (Bohbot et al. 1998, 2004; Iaria et al. 2003). The *perirhinal cortex*, another region in inferotemporal cortex, may be needed to code the surface features or texture of the landmarks and scenes (Murray & Bussey, 1999, 2001; Murray & Richmond, 2001; Burgess et al. 2002; Lee et al. 2005). Many of these structures have reciprocal anatomical connections with each other and with the hippocampus (Cammalleri et al. 1996; Van Hoesen et al. 1993; Suzuki & Amaral, 1994; Rockland & Van Hoesen, 1999; Lavenex et al. 2002), forming a spatial network.

Rosenbaum et al. (2005a) illustrate these points well in a recent study of spatial memory in a taxi-driver with AD and extensive bilateral HC/MTL and parahippocampal degeneration, but relatively preserved temporal neocortex. His performance was compared to that of a former taxi-driver whose encephalitis left him

with left temporal neocortical damage but less extensive hippocampal atrophy, and to eight age-matched controls. The tests were identical to those administered to KC in his home neighbourhood. In this case, however, the area investigated was a 5 km<sup>2</sup> section of downtown Toronto which contained many of the city's major landmarks. Except for sketch mapping, which proved too complicated for this large area, the remaining tests became part of a regular battery called the Toronto Public Places Test (TPPT). All the participants were familiar with the area, though they had visited it rarely if ever in the last decade. The taxi-driver with AD performed as well or better than all the other participants on every test, except for recognition of major landmarks from their pictures or imagery of their visual appearance from their names, though he had no difficulty in describing their function or spatial location. Subsequent tests showed that he had equal difficulty in visual recognition of world landmarks, such as the Eiffel Tower or Taj Mahal, but not of famous faces. These results point to a landmark agnosia, which in his case we believe is associated with degeneration of the parahippocampal gyrus in a region posterior to the parahippocampal place area (Epstein & Kanwisher, 1998) which is preserved in the other patients. Importantly, mental, spatial navigation, including that based on allocentric information, was spared in AD, although volumetric analysis confirmed that atrophy claimed over 50% of the hippocampus and inferior temporal cortex.

In each of these studies, it is possible that the remaining hippocampal tissue mediates the preserved performance on allocentric tests of spatial navigation. We believe this is unlikely for two reasons: (1) comparable lesions produce deficits, sometimes quite severe ones, on anterograde tests of spatial memory, and on retrograde tests of autobiographical memory; and (2) in Teng & Squire (1999), the patient's lesion encompasses almost the entire MTL leaving little, if any, viable hippocampal tissue. These reasons notwithstanding, we conducted functional neuroimaging studies to determine more decisively whether the hippocampus was implicated in performance on tests of remote spatial memory.

#### Neuroimaging studies

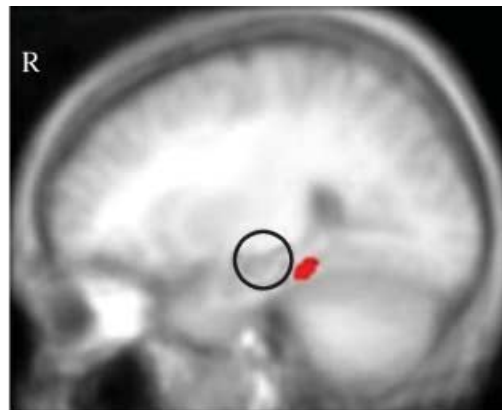
There are only a handful of functional neuroimaging studies on remote spatial memory. Maguire et al. (1997) tested the ability of experienced London taxi-drivers to find new routes from one location to another when

familiar routes were blocked. They report hippocampal activation associated with success in novel way-finding, but the region of activation is on the border of the hippocampus and parahippocampal cortex, not in the hippocampus itself. Niki & Luo (2002) and Mayes et al. (2004) report activation in the body of the hippocampus while imagining to navigate through environments experienced recently or long ago, but these activations are related either to the recency of the memory or, more likely, to the vividness (number of details of the environment and autobiographical context) of the experience while navigating, much as we found for hippocampal activation of episodic memory (see above pp. 47–49). A similar explanation may account for the finding of Maguire et al. (2000) that the size of the hippocampus in London taxi-drivers is correlated with years of experience in driving a taxi and with performance on tests of their knowledge of London streets.

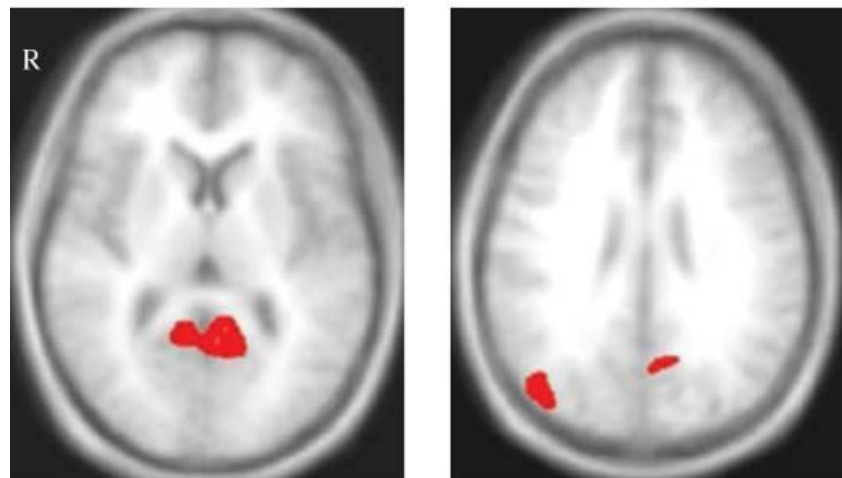
In order to identify the network of brain regions implicated in lesion and functional neuroimaging studies of spatial memory and navigation, and to determine whether the MTL was implicated, we

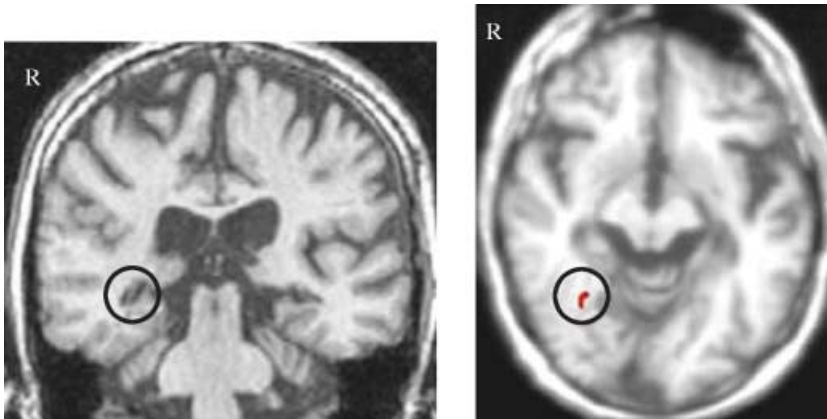
modified the TPPT for functional neuroimaging in young, healthy adults (Rosenbaum et al. 2004a). We found that the level of activation in each region varied with the particular demands of each task. For example, as predicted, the superior-medial parietal cortex was implicated more in egocentric tests of spatial memory (tests (4) and (7) above), whereas the retrosplenial cortex was implicated more on allocentric tests (tests (3), (5) and (6) above). Also as predicted by our studies with patients with hippocampal lesions, the hippocampus proper was not activated on any of the tests more than on the baseline control task, though a region on the border of the posterior hippocampus and parahippocampal cortex was active (Fig. 7), as noted by Maguire et al. (1997).

To test further whether the remaining hippocampal tissue in K.C. was viable and could support performance on the neighbourhood tests of navigation, we conducted a functional neuroimaging study using a modified version of the same tests. No hippocampal activation was found in K.C. or controls who moved away 20 years ago, on any tests of remote spatial memory



**Fig. 7** Brain regions activated in the comparison of all remote spatial memory tasks with the perceptual baseline task. The functional maps are overlaid on the averaged anatomical scans from all participants in relevant sagittal and axial views. The right hemisphere is shown on the left side of the images. Images were thresholded at  $P < 0.001$ , corrected. Areas of activity common across tasks included right parahippocampal gyrus (top), left retrosplenial cortex (bottom left) and right superior occipital cortex (bottom right). The hippocampus (open circle) was not activated in any task.





**Fig. 8** Structural scan of K.C.'s brain showing small amount of remaining hippocampal tissue that was unactivated (left); for comparison see right parahippocampal activation in parahippocampal cortex during remote spatial memory tasks (right).

except when K.C. viewed familiar landmarks which he did not recognize, and considered novel. The latter finding is important because it shows that the remaining tissue is viable, and is active when K.C. perceives something to be unfamiliar (novel), but not when he is navigating mentally through his environment (Rosenbaum et al. 2005b). As with the TPPT tests, the same extra-hippocampal areas were activated, the amount and pattern of activation being determined by the demands of each particular test (Fig. 8).

The results of our studies on remote spatial memory, like those of Burgess, Maguire and their collaborators (Burgess, 2002; Burgess et al. 2002; Hartley et al. 2003) on anterograde spatial memory, suggest that remote spatial and episodic memory have much in common, though we differ in our conception of the role of the hippocampus. Whereas they believe the hippocampus is implicated in all forms of allocentric spatial representations, our results suggest that at least for pre-morbidly familiar environments, some allocentric representations exist independently of it. Our studies suggest that an episodic-semantic distinction may be as usefully applied to spatial memory as to nonspatial memory, and thus provides a unified framework for conceptualizing hippocampal–neocortical interactions. In this framework, *detailed perceptual-spatial representations* of environments (corresponding to episodic, autobiographical memory) are hippocampally dependent and distinguished from *schematic or coarse, but allocentric, representations of the topography* (corresponding to semantic memory) that can exist independently of the hippocampus. The hippocampal code serves as a pointer or index to regions of neocortex (e.g. parahippocampal and perirhinal cortex) where these different kinds of information are stored and binds them into detailed representations that allow

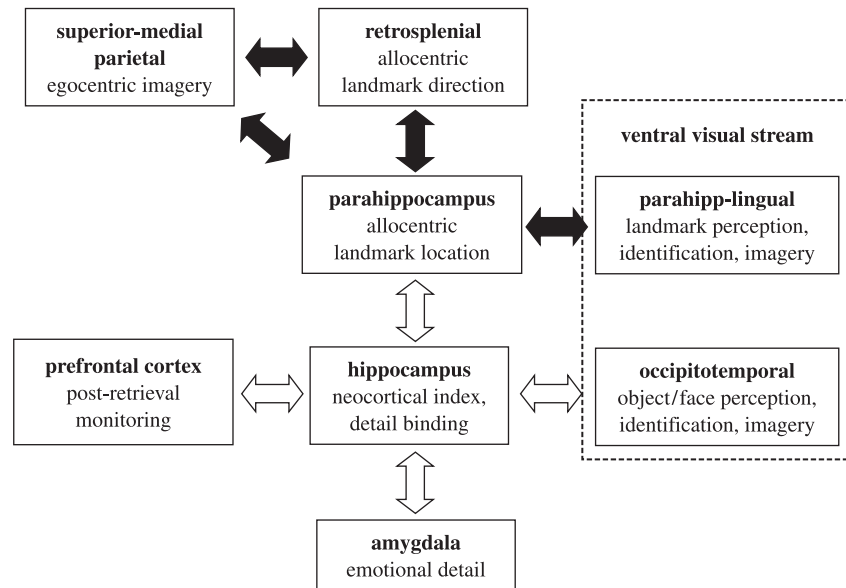
one to re-experience the environment as one takes a mental walk through it (see Fig. 9). A similar proposal has been advanced by Burgess et al. (2002) regarding the episodic component, but not about the semantic one. *Schematic*, allocentric topographical representations, however, are sufficient to allow one to navigate in the environment and recognize those features which provide salient cues for navigation, without supporting a rich representation needed to re-experience the environment, or recognize noncritical elements of it (see Rosenbaum et al. 2000, 2001; for earlier versions of this view).

#### Summary and theoretical implications

Overall, findings from both lesion and functional neuroimaging studies provide compelling evidence that the hippocampus is not needed for retention and retrieval of some remote spatial memories, even those capturing some allocentric information, for the purposes of navigation. These observations, therefore, pose a challenge to the original formulation of cognitive map theory, which proposed that the hippocampus is crucial for representing all forms of allocentric spatial information necessary for navigation, no matter how long ago that information was acquired. In agreement with cognitive map theory, however, the hippocampus is required for the retention of detailed spatial memories of the environment, such as the appearance of local elements that can support a rich, re-experiencing of the environment. Some supportive evidence has been presented from lesion (Rosenbaum et al. 2000) and neuroimaging studies (Niki & Luo, 2002; Mayes et al. 2004; Rosenbaum et al. submitted), but more research is needed to confirm these findings and to test alternative interpretations of them. Overall, however, the findings on spatial memory are consistent with MTT's postulate



**Fig. 9** Graphic illustration of a hippocampal–neocortical framework of long-term context-free and context-dependent memory. The open arrows represent connections between the hippocampus and specialized neocortical regions that allow for the reconstruction in memory of newly formed traces and of event-specific details. The closed arrows represent an example of a subnetwork of structures supporting one class of schematic information (spatial) that has been abstracted over time and that can exist independently of the hippocampus.



that the hippocampus is crucial for detailed re-experiencing of the past, but not for retention and retrieval of generic or semantic memory for which the neocortex suffices. The standard model would predict the latter but has difficulty accounting for the continuing contribution of the hippocampus to perceptually detailed aspects of remote spatial memory.

## Conclusions

The evidence we reviewed supports a unified account of episodic, semantic and spatial memory based on MTT. The account challenges many of the basic tenets of the standard consolidation model and is inconsistent with one aspect of cognitive map theory of hippocampal function. Episodic and spatial memory have been related to one another and viewed as reflecting the function of the same hippocampal substrate (O'Keefe & Nadel, 1978; Cohen & Eichenbaum, 1993; Burgess et al. 2001, 2002; Eichenbaum, 2001). The lesion and neuroimaging studies we reviewed suggest that retention and recovery of detailed memories for autobiographical episodes, and perhaps even for public events and personalities, always depend on the hippocampus (Sanders & Warrington, 1971; Nadel & Moscovitch, 1997; Fujii et al. 2000; Maguire, 2001a; Ryan et al. 2001; Corkin, 2002; Maguire & Frith, 2003; Piolino et al. 2003; Addis et al. 2004a; Gilboa et al. 2004), whereas semantic memories may benefit from the hippocampus but can survive without it (Manns et al. 2003; Westmacott et al. 2004b; but see Fujii et al. 2000).

These findings run counter to the traditional view that the role of the hippocampal complex in memory is time-limited for *all* memories, being needed only until consolidation of the memory trace or engram in neocortex (or elsewhere) is complete (Milner et al. 1998; Haist et al. 2001; Bayley et al. 2003; Squire et al. 2004). According to the new account, based on MTT, vividness and experiential aspects of episodic memory, rather than its age or semantic content, are considered the crucial factors associated with hippocampal activation. This account also is consistent with evidence on anterograde memory showing that recollection, an index of experiential factors, is a determinant of hippocampal involvement in memory (Aggleton & Brown, 1999; Eldridge et al. 2000; D. Moscovitch & McAndrews, 2000; Holdstock et al. 2002a; Fortin et al. 2004; Ranganath et al. 2004).

We believe that a similar MTT-based account applies to spatial memory. During acquisition, the hippocampus is crucial for the formation and retention of cognitive maps of the environment which are allocentric (viewpoint-independent) representations that code for configural spatial relations among objects, and possibly the geometry and topography of the environment. These allocentric representations are postulated to form the core of hippocampal, event or experiential codes, to which information about other spatial and nonspatial aspects of an episode (such as texture of stimuli) are bound (O'Keefe & Nadel, 1978; Moscovitch, 1995; Eichenbaum & Cohen, 2001; Burgess et al. 2002). As such, the hippocampus supports a rich representation of the

environment which is the spatial analogue of vivid, episodic memory, and may be an important aspect of it. Studies of anterograde memory generally support this view, and suggest that subregions of the MTL, as well as other regions of neocortex, are likely to contribute differentially to different aspects of spatial memory (Murray & Mishkin, 1998; Burgess et al. 2002; Rosenbaum et al. 2004a, submitted), just as they do for episodic memory. With repeated experience in navigating the environment, however, neocortical structures abstract the statistical regularities from the episodic, spatial representations, just as they do for other types of memory, and are capable of storing schematic, allocentric representations that can be used for navigation.

The results we reviewed support this interpretation by showing that people with hippocampal lesions perform well on a variety of navigation tests in a familiar environment, including tests of allocentric spatial memory, and by showing that the hippocampus is not activated in normal people on any of those tests of a familiar environment. Consistent with this observation, we have recently shown that rats reared for three months in a complex environment continue to navigate normally in it even after sustaining large hippocampal lesions (Wincour et al. 2005).

We also reviewed some suggestive, though not conclusive, evidence that a rich re-experiencing of the environment will continue to depend on the hippocampus no matter how old the spatial memory is, just as does re-experiencing autobiographical episodes.

Although new evidence suggests modifications to MTT will be required, this theory continues to provide the best, and most unified, account of the evidence on remote episodic, semantic, and spatial memory. It also points the way to developing a parsimonious and unified account of the function of the MTL, and related structures, in representing recent and remote memories.

## References

- Addis DR, Moscovitch M, Crawley AP, McAndrews MP** (2004a) Recollective qualities modulate hippocampal activation during autobiographical memory retrieval. *Hippocampus* **14**, 752–762.
- Addis DR, McIntosh AR, Moscovitch M, Crawley AP, McAndrews MP** (2004b) Characterising the spatial and temporal features of autobiographical memory retrieval networks: a partial least squares approach. *NeuroImage* **23**, 1460–1471.
- Aggleton JP, Brown MW** (1999) Episodic memory, amnesia, and the hippocampal-anterior thalamic axis. *Behav. Brain Sci.* **22**, 425–489.
- Aggleton JP, McMackin D, Carpenter K, Hornak J, Kapur N, Halpin S, et al.** (2000) Differential cognitive effects of colloid cysts in the third ventricle that spare or compromise the fornix. *Brain* **123**, 800–815.
- Aguirre GK, D'Esposito M** (1999) Topographical disorientation: a synthesis and taxonomy. *Brain* **122**, 1613–1628.
- Aguirre GK, Detre JA, Also DC, D'Esposito M** (1996) The parahippocampus subserves topographical learning in man. *Cereb Cortex* **6**, 823–829.
- Atkinson RC, Juola JF** (1973) Factors influencing speed and accuracy of word recognition. In: *Attention and Performance: IV* (ed. Kornblum S). New York, USA: Academic Press.
- Barrash J** (1998) A historical review of topographical disorientation and its neuroanatomical correlates. *J. Clin. Exp. Neuropsychol.* **20**, 807–827.
- Bayley PJ, Hopkins RO, Squire LR** (2003) Successful recollection of remote autobiographical memories by amnesic patients with medial temporal lobe lesions. *Neuron* **38**, 135–144.
- Bisiach E, Brouchon M, Poncet M, Rusconi ML** (1993) Unilateral neglect in route description. *Neuropsychologia* **31**, 1255–1262.
- Blumenfeld H** (2002) *Neuroanatomy Through Clinical Cases*. Sunderland, MA, USA: Sinauer Associates, Inc.
- Bohbot VD, Iaria G, Petrides M** (2004) Hippocampal function and spatial memory: evidence from functional neuroimaging in healthy participants and performance of patients with medial temporal lobe resections. *Neuropsychology* **18**, 418–425.
- Bohbot VD, Kalina M, Stepankova K, Spackova N, Petrides M, Nadel L** (1998) Spatial memory deficits in patients with lesions to the right hippocampus and to the right parahippocampal cortex. *Neuropsychologia* **36**, 1217–1238.
- Bowers D, Verfaellie M, Valenstein E, Heilman KM** (1988) Impaired acquisition of temporal information in retrosplenial amnesia. *Brain Cogn.* **8**, 47–66.
- Burgess N** (2002) The hippocampus, space, and viewpoints in episodic memory. *Q. J. Exp. Psychol. A.* **55**, 1057–1080.
- Burgess N, Becker S, King JA, O'Keefe J** (2001) Memory for events and their spatial context: Models and experiments. *Philos. Trans. R. Soc. Lond. B. Biol. Sci.* **356**, 1493–1503.
- Burgess N, Maguire EA, O'Keefe J** (2002) The human hippocampus and spatial and episodic memory. *Neuron* **35**, 625–641.
- Burgess PW, Shallice T** (1996) Confabulation and the control of recollection. *Memory* **4**, 359–411.
- Burnham WH** (1904) Retroactive amnesia: Illustrative cases and a tentative explanation. *Am. J. Psychol.* **14**, 382–396.
- Byrne RW** (1982) Geographical knowledge and orientation. In: *Normality and Pathology in Cognitive Functions* (ed. Ellis AW), pp. 239–264. London, UK: Academic Press.
- Cabeza R, Nyberg L** (2000) Imaging cognition II: An empirical review of 275 PET and fMRI studies. *J. Cogn. Neurosci.* **12**, 1–47.
- Cammalleri R, Gangitano M, D'Amelio M, Raieli V, Raimondo D, Camarda R** (1996) Transient topographical amnesia and cingulate cortex damage: a case report. *Neuropsychologia* **34**, 321–326.
- Caza N, McAndrews MP, Hoque T, Ziegler M, Crawley M, Moscovitch M** (2004) Neural basis for remembering and knowing in associative memory. *Paper Presented at a Conference on Cognitive Neuroscience, Montreal, July, 2004.*

- Cermak LS** (1982) *Human Memory and Amnesia*. Hillsdale, NJ, USA: Lawrence Erlbaum Associates.
- Cermak LS, O'Connor M** (1983) The anterograde and retrograde retrieval ability of a patient with amnesia due to encephalitis. *Neuropsychologia* **21**, 213–234.
- Cipilotti L, Shallice T, Chan D, Fox N, Scahill R, Harrison G, Stevens J, Rudge P** (2001) Long-term retrograde amnesia: The crucial role of the hippocampus. *Neuropsychologia* **39**, 151–172.
- Cohen NJ, Eichenbaum H** (1993) *Memory, Amnesia, and the Hippocampal System*. Cambridge, MA, USA: MIT Press.
- Cohen NJ, Squire LR** (1980) Preserved learning and retention of pattern-analyzing skill in amnesia: dissociation of knowing how and knowing that. *Science* **210**, 207–210.
- Conway MA, Fthenaki AK** (2000) Disruption and loss of autobiographical memory. In: *Handbook of Neuropsychology: Memory* (ed. Cermak LS), pp. 257–288. Amsterdam, the Netherlands: Elsevier.
- Conway MA, Pleydell-Pearce CW** (2000) The construction of autobiographical memories in the self-memory system. *Psychol. Rev.* **107**, 261–288.
- Conway MA, Turk DJ, Miller SL, Logan J, Nebes RD, Meltzer CC, Becker JT** (1999) A positron emission tomography (PET) study of autobiographical memory retrieval. *Memory* **5–6**, 679–702.
- Corkin S** (1984) Lasting consequences of bilateral medial temporal lobectomy: Clinical course and experimental findings in H.M. *Semin. Neurol.* **4**, 252–262.
- Corkin S** (2002) What's new with the amnesic patient H.M.? *Nat. Rev. Neurosci.* **3**, 153–160.
- Corkin S, Amaral DG, Gonzalez G, Johnson KA, Hyman BT** (1997) H.M.'s medial temporal lobe lesion: Findings from magnetic resonance imaging. *J. Neurosci.* **17**, 3964–3979.
- Craik FIM, Moroz TM, Moscovitch M, Stuss DT, Winocur G, Tulving E, et al.** (1999) In search of the self, a positron emission tomography study. *Psychol. Sci.* **10**, 26–34.
- Crovitz HF, Schiffman H** (1974) Frequency of episodic memories as a function of their age. *Bull. Psychon. Soc.* **4**, 519–521.
- Davachi L, Mitchell JP, Wagner AD** (2003) Multiple routes to memory: Distinct medial temporal lobe processes build item and source memories. *Proc. Natl. Acad. Sci. USA* **100**, 2157–2162.
- De Renzi E** (1982) *Disorders of Space Exploration and Cognition*. Chichester, UK: John Wiley.
- Dolcos F, LaBar KS, Cabeza R** (2002) Interaction between the amygdala and the medial temporal lobe memory system predicts better memory for emotional events. *Neuron* **42**, 855–863.
- Douville K, Woodard JL, Seidenberg M, Miller SK, Leveroni CL, Nielson KA, et al.** (2005) Medial temporal lobe activity for recognition of recent and remote famous names: an event-related fMRI study. *Neuropsychologia* **43**, 693–703.
- Dudai Y** (2004) The neurobiology of consolidations, or, how stable is the engram? *Annu. Rev. Psychol.* **55**, 51–86.
- Eichenbaum H** (2001) The hippocampus and declarative memory: Cognitive mechanisms and neural codes. *Behav. Brain Res.* **127**, 199–207.
- Eichenbaum H, Cohen NJ** (2001) *From Conditioning to Consciousness: Memory Systems of the Brain*. London, UK: Oxford University Press.
- Eichenbaum H, Otto T, Cohen NJ** (1994) Two functional components of the hippocampal memory system. *Behav. Brain Sci.* **17**, 449–518.
- Eldridge LL, Knowlton BJ, Furmanski CS, Bookheimer SY, Engel SA** (2000) Remembering episodes: a selective role for the hippocampus during retrieval. *Nat. Neurosci.* **3**, 1149–1152.
- Epstein R, Graham KS, Downing PE** (2003) Viewpoint-specific scene representations in human parahippocampal cortex. *Neuron* **37**, 865–876.
- Epstein R, Harris A, Stanley D, Kanwisher N** (1999) The parahippocampal place area: Recognition, navigation, or encoding? *Neuron* **23**, 115–125.
- Epstein R, Kanwisher N** (1998) A cortical representation of the local visual environment. *Nature* **392**, 598–601.
- Eslinger PJ** (1998) Autobiographical memory after temporal lobe lesions. *Neurocase* **4**, 481–495.
- Eustache F, Piolino P, Giffard B, Viader F, De La Sayette V, Baron JC, Desgranges B** (2003) In the course of time: a PET study of the cerebral substrates of autobiographical amnesia in Alzheimer's disease. *Brain* **127**, 1549–1560.
- Farrell MJ** (1996) Topographical disorientation. *Neurocase* **2**, 509–520.
- Fletcher PC, Frith CD, Baker SC, Shallice T, Frackowiak RS, Dolan RJ** (1995) The mind's eye – precuneus activation in memory-related imagery. *NeuroImage* **2**, 195–200.
- Fletcher PC, Henson RN** (2001) Frontal lobes and human memory: insights from functional neuroimaging. *Brain* **124**, 849–881.
- Fortin NJ, Wright SP, Eichenbaum H** (2004) Recollection-like memory retrieval in rats is dependent on the hippocampus. *Nature* **431**, 188–191.
- Frankland PW, Bontempi B** (2005) The organization of recent and remote memories. *Nat. Rev. Neurosci.* **6**, 119–130.
- Fujii T, Moscovitch M, Nadel L** (2000) Consolidation, retrograde amnesia, and the temporal lobe. In: *The Handbook of Neuropsychology*, 2nd edn, Vol. 4 (eds Boller F, Grafman J, section ed. Cermak LS), pp. 223–250. Amsterdam, the Netherlands: Elsevier.
- Gadian DG, Aicardi J, Watkins KE, Porter DA, Mishkin M, Vargha-Khadem F** (2000) Developmental amnesia associated with early hypoxic-ischaemic injury. *Brain* **123**, 499–507.
- Gilboa A** (2004a) *Neuropsychology of Remote and Recent Autobiographical Memory*. Unpublished doctoral Thesis, University of Toronto, Toronto, Canada.
- Gilboa A** (2004) Autobiographical and episodic memory—one and the same! Evidence from prefrontal activation in neuroimaging studies. *Neuropsychologia* **47**, 1336–1349.
- Gilboa A, Moscovitch M** (2002) The cognitive neuroscience of confabulation: A review and a model. In: *Handbook of Memory Disorders*, 2nd edn (eds Baddeley AD, Kopelman MD, Wilson BA), pp. 315–342. London, UK: Wiley.
- Gilboa A, Rosenbaum RS, Westmacott R, Winocur G, Moscovitch M** (2005a) Recognition of remote episodic details is specifically compromised following lesions to the fornices and left basal forebrain, (In press.)
- Gilboa A, Ramirez J, Köhler S, Westmacott R, Black SE, Moscovitch M** (2005) Retrieval of autobiographical memory in Alzheimer's disease: Relation to volumes of medial temporal lobe and other structures. *Hippocampus* **15**, 535–550.

- Gilboa A, Winocur G, Grady CL, Hevenor SJ, Moscovitch M** (2004) Remembering our past: Functional neuroanatomy of recollection of recent and very remote personal events. *Cereb. Cortex* **14**, 1214–1225.
- Graham KS** (1999) Semantic dementia: a challenge to the multiple-trace theory? *Trends. Cogn. Sci.* **3**, 85–87.
- Graham KS, Hodges JR** (1997) Differentiating the roles of the hippocampal system and the neocortex in long-term memory storage. *Neuropsychology* **11**, 77–89.
- Graham KS, Kropelnicki A, Goldman WP, Hodges JR** (2003a) Two further investigations of autobiographical memory in semantic dementia. *Cortex* **39**, 729–750.
- Graham KS, Lee ACH, Brett M, Patterson K** (2003b) The neural basis of autobiographical and semantic memory: New evidence from three PET studies. *Cogn. Affect. Behav. Neurosci.* **3**, 234–254.
- Graham KS, Patterson K, Hodges JR** (1999) Episodic memory: New insights from the study of semantic dementia. *Curr. Opin. Neurobiol.* **9**, 245–250.
- Graham KS, Simons JS, Pratt KH, Patterson K, Hodges JR** (2000) Insights from semantic dementia on the relationship between episodic and semantic memory. *Neuropsychologia* **38**, 313–324.
- Greenberg DL, Rubin DC** (2003) The neuropsychology of autobiographical memory. *Cortex* **39**, 687–728.
- Habib M, Sirigu A** (1987) Pure topographical disorientation: a definition and anatomical basis. *Cortex* **23**, 73–85.
- Haist F, Bowden Gore J, Mao H** (2001) Consolidation of human memory over decades revealed by functional magnetic resonance imaging. *Nat. Neurosci.* **4**, 1139–1145.
- Hartley T, Maguire EA, Spiers HJ, Burgess N** (2003) The well-worn route and the path less traveled: Distinct neural bases of route following and wayfinding in humans. *Neuron* **37**, 877–888.
- Haxby JV, Petit L, Ungerleider LG, Courtney SM** (2000) Distinguishing the functional roles of multiple regions in distributed neural systems for visual working memory. *NeuroImage* **11**, 380–391.
- Heilman KM, Bowers D, Watson RT, Day A, Valenstein E, Hammond E, et al.** (1990) Frontal hypermetabolism and thalamic hypometabolism in a patient with abnormal orienting and retrosplenial amnesia. *Neuropsychologia* **28**, 161–169.
- Holdstock JS, Mayes AR, Roberts N, Cezayirli E, Isaac CL, O'Reilly RC, Norman KA** (2002a) Under what conditions is recognition spared relative to recall after selective hippocampal damage? *Hippocampus* **12**, 341–351.
- Holdstock JS, Mayes AR, Isaac CL, Roberts JN** (2002b) Differential involvement of the hippocampus and temporal cortices in rapid and slow learning of new semantic information. *Neuropsychologia* **40**, 748–768.
- Iaria G, Petrides M, Dagher A, Pike B, Bohbot VD** (2003) Cognitive strategies dependent on the hippocampus and caudate nucleus in human navigation: variability and change with practice. *J. Neurosci.* **23**, 5945–5952.
- Incisa della Rocchetta A, Cipolotti L, Warrington EK** (1996) Topographical disorientation: selective impairment of locomotor space? *Cortex* **32**, 727–735.
- Ivanoiu A, Cooper JM, Shanks JM, Venneri A** (2004) Retrieval of episodic and semantic autobiographical memories in early Alzheimer's Disease and semantic dementia. *Cortex* **40**, 173–175.
- Kandel ER** (2001) The molecular biology of memory storage: a dialogue between genes and synapses. *Science* **294**, 1030–1038.
- Kapur N** (1999) Syndromes of retrograde amnesia: a conceptual and empirical analysis. *Psychol. Bull.* **125**, 800–825.
- Kapur N, Friston KJ, Young A, Frith CD, Frackowiak RS** (1995) Activation of human hippocampal formation during memory for faces: a PET study. *Cortex* **31**, 99–108.
- Kapur N, Thompson P, Evans J, Abbott P** (2002) Can epilepsy-related phenomena unblock some of the secrets of long-term memory? *Frontiers of Human Memory* (eds Yamadori A, Kawashima R., Fujii T, Suzuki K), pp. 137–150. Sendai, Japan: Tohoku University Press.
- Kinsbourne M, Wood F** (1975) Short-term memory processes and the amnesic syndrome. In: *Short-Term Memory* (eds Deutsch D, Deutsch AJ), pp. 258–291. New York, USA: Academic Press.
- Kitchener EG, Hodges JR, McCarthy R** (1998) Acquisition of post-morbid vocabulary and semantic facts in the absence of episodic memory. *Brain* **121**, 1313–1327.
- Kitchener EG, Squire LR** (2000) Impaired verbal category learning in amnesia. *Behav. Neurosci.* **114**, 907–911.
- Kopelman MD, Lasserson D, Kingsley DR, Bello F, Rush C, Stanhope N, et al.** (2003) Retrograde amnesia and the volume of critical brain structures. *Hippocampus* **13**, 879–891.
- Kopelman MD, Stanhope N, Kingsley D** (1999) Retrograde amnesia in patients with diencephalic, temporal lobe or frontal lesions. *Neuropsychologia* **37**, 939–958.
- Kopelman MD, Wilson BA, Baddeley AD** (1989) The autobiographical memory interview: a new assessment of autobiographical and personal semantic memory in amnesic patients. *J. Clin. Exp. Neuropsychol.* **5**, 724–744.
- Lavenex P, Suzuki WA, Amaral DG** (2002) Perirhinal and parahippocampal cortices of the macaque monkey: projections to the neocortex. *J. Comp. Neurol.* **447**, 394–420.
- Lee CH, Bussey TJ, Murray EA, Saksida LM, Epstein RA, Kapur N, et al.** (2005) Perceptual deficits in amnesia: challenging the medial temporal lobe 'mnemonic' view. *Neuropsychologia* **43**, 1–11.
- Leveroni CL, Seidenberg M, Mayer AR, Mead LA, Binder JR, Rao SM** (2000) Neural systems underlying the recognition of familiar and newly learned faces. *J. Neurosci.* **20**, 878–886.
- Levine B, Svoboda E, Hay JF, Winocur G, Moscovitch M** (2002) Aging and autobiographical memory: Dissociating episodic from semantic retrieval. *Psychol. Aging* **17**, 677–689.
- Maguire EA** (2001a) Neuroimaging studies of autobiographical event memory. *Philos. Trans. R. Soc. Lond. B. Biol. Sci.* **356**, 1441–1451.
- Maguire EA** (2001b) The retrosplenial contribution to human navigation: a review of lesion and neuroimaging findings. *Scand. J. Psychol.* **42**, 225–238.
- Maguire EA, Frackowiak RS, Frith CD** (1997) Recalling routes around London: activation of the right hippocampus in taxi drivers. *J. Neurosci.* **17**, 7103–7110.
- Maguire EA, Frith CD** (2003) Lateral asymmetry in the hippocampal response to the remoteness of autobiographical memories. *J. Neurosci.* **23**, 5302–5307.
- Maguire EA, Henson RN, Nummery CJ, Frith CD** (2001) Activity in prefrontal cortex, not hippocampus, varies parametrically

- with the increasing remoteness of memory. *Neuroreport* **12**, 441–444.
- Maguire EA, Mummery CJ** (1999) Differential modulation of a common memory retrieval network revealed by positron emission tomography. *Hippocampus* **9**, 54–61.
- Maguire EA, Gadian DG, Johnsrude IS, Good CD, Ashburner J, Frackowiak RS, Frith CD** (2000) Navigation-related structural change in the hippocampi of taxi drivers. *Proc. Natl. Acad. Sci. USA* **97**, 4398–4403.
- Maguire EA, Vargha-Khadem F, Mishkin M** (2001) The effects of bilateral hippocampal damage on fMRI regional activations and interactions during memory retrieval. *Brain* **124**, 1156–1170.
- Mair WG, Warrington EK, Weiskrantz L** (1979) Memory disorder in Korsakoff's psychosis: a neuropathological and neuropsychological investigation of two cases. *Brain* **102**, 749–783.
- Mandler G** (1980) Recognizing the judgement of previous occurrence. *Psychol. Rev.* **87**, 252–271.
- Manns JR, Hopkins RO, Squire LR** (2003) Semantic memory and the human hippocampus. *Neuron* **38**, 127–133.
- Martin A, Chao L** (2001) Semantic memory and the brain: structure and processes. *Curr. Opin. Neurobiol.* **11**, 194–201.
- Mayes AR, Holdstock JS, Isaac CL, Montaldi D, Grigor J, Gummer A, et al.** (2004) Associative recognition in a patient with selective hippocampal lesions and relatively normal item recognition. *Hippocampus* **14**, 763–784.
- Mayes AR, Isaac CL, Holdstock JS, Cariga P, Gummer A, Roberts N** (2003) Long-term amnesia: a review and detailed illustrative case study. *Cortex* **39**, 567–603.
- McClelland JL, McNaughton BL, O'Reilly RC** (1995) Why there are complementary learning systems in the hippocampus and neocortex: Insights from the successes and failures of connectionist models of learning and memory. *Psychol. Rev.* **102**, 419–457.
- McClelland JL, Rogers TT** (2003) The parallel distributed processing approach to semantic memory. *Nat. Rev. Neurosci.* **4**, 310–322.
- McGaugh JL** (2000) Memory – a century of consolidation. *Science* **287**, 248–251.
- McGaugh JL** (2004) The amygdala modulates the consolidation of memories of emotionally arousing experiences. *Annu. Rev. Neurosci.* **27**, 1–28.
- Milner B** (1966) Amnesia following operation on the temporal lobe. In: *Amnesia* (eds Whitty CWM, Zangwill OL), pp. 109–133. London, UK: Butterworth.
- Milner B** (1974) Functional recovery after lesions of the nervous system. 3. Developmental processes in neural plasticity. Sparing of language functions after early unilateral brain damage. *Neurosci. Res. Program Bull.* **12**, 213–217.
- Milner B, Corkin S, Teuber HL** (1968) Further analysis of the hippocampal amnesic syndrome: 14-year follow-up of H.M. *Neuropsychologia* **6**, 215–234.
- Milner AD, Goodale MA** (1995) *The Visual Brain in Action*. Oxford, UK: Oxford University Press.
- Milner B, Squire LR, Kandel ER** (1998) Cognitive neuroscience and the study of memory. *Neuron* **20**, 445–468.
- Moscovitch M** (2001) Memory consolidation. In: *Encyclopedia of Cognitive Science* (ed. Nadel L). New York, USA: Nature Publishing Group.
- Moscovitch M** (1982) Multiple dissociation of function in the amnesic syndrome. In: *Human Memory and Amnesia* (ed. Cermak LS), pp. 337–370. Hillsdale, NJ, USA: Lawrence Erlbaum Associates.
- Moscovitch M** (1992) Memory and working with memory: a component process model based on modules and central systems. *J. Cogn. Neurosci.* **4**, 257–267.
- Moscovitch M** (1995) Recovered consciousness: a hypothesis concerning modularity and episodic memory. *J. Clin. Exper. Neuropsychol.* **17**, 276–291.
- Moscovitch M** (2000) Theories of memory and consciousness. In: *The Oxford Handbook of Memory* (eds Tulving E, Craik FIM), pp. 609–625. Oxford, UK: Oxford University Press.
- Moscovitch DA, McAndrews MP** (2002) Material-specific deficits in 'remembering' in patients with unilateral temporal lobe epilepsy and excisions. *Neuropsychologia* **40**, 1335–1342.
- Moscovitch M, Umiltà C** (1990) Modularity and neuropsychology: Modules and central processes in attention and memory. In: *Modular Deficits in Alzheimer's Disease* (ed. Schwartz MF), pp. 1–59. Cambridge, MA, USA: MIT Press/Bradford.
- Moscovitch M, Vriezen E, Goshen-Gottstein Y** (1993) Implicit tests of memory in patients with focal lesions or degenerative brain disorders. In: *The Handbook of Neuropsychology*, Vol. 8 (eds Boller F, Spinnler H), pp. 133–173. Amsterdam, the Netherlands: Elsevier.
- Moscovitch M, Westmacott R, Gilboa A, Addis DR, Rosenbaum RS, Viskontas I, et al.** (2005) Hippocampal complex contributions to retention and retrieval of recent and remote episodic and semantic memories: Evidence from behavioural and neuroimaging studies of normal and brain-damaged people. In: *Dynamic Cognitive Processes* (eds Ohta N, MacLeod CM, Uttl B), pp. 333–380. Tokyo, Japan: Springer-Verlag.
- Moscovitch M, Winocur G** (2002) The frontal cortex and working with memory. In: *The Frontal Lobes* (eds Stuss DT, Knight RT), pp. 188–209. Oxford, UK: Oxford University Press.
- Moscovitch M, Yaschyshyn T, Ziegler M, Nadel L** (1999) Remote episodic memory and amnesia: Was Endel Tulving right all along? *Memory, Consciousness and the Brain: the Tallinn Conference* (ed. Tulving E), pp. 331–345. New York, USA: The Psychology Press.
- Moss HE, Kopelman MD, Cappelletti M, de Mornay Davies P, Jaldow E** (2003) Lost for words or loss of memories? Autobiographical memory in semantic dementia. *Cogn. Neuropsychol.* **20**, 703–732.
- Müller GE, Pilzecker A** (1900) Experimentelle Beiträge zur Lehre vom Gedächtnis [Experimental contributions to the theory of memory]. *Zeitschrift für Psychologie und Physiologie der Sinnesorgane* **51**, 1–288 (summarized by McDougall W, Critical Notices). *Am. J. Psychol.* 388–394.
- Mummery CJ, Patterson K, Price CJ, Ashburner J, Frackowiak RSJ, Hodges JR** (2000) A voxel-based morphometry study of semantic dementia: Relationship between temporal lobe atrophy and semantic dementia. *Ann. Neurol.* **47**, 36–45.
- Murray EA, Bussey TJ** (1999) Perceptual-mnemonic functions of the perirhinal cortex. *Trends. Cogn. Sci.* **3**, 142–151.
- Murray EA, Bussey TJ** (2001) Consolidation and the medial temporal lobe revisited: Methodological considerations. *Hippocampus* **11**, 1–7.
- Murray EA, Mishkin M** (1998) Object recognition and location

- memory in monkeys with excitotoxic lesions of the amygdala and hippocampus. *J. Neurosci.* **18**, 6568–6582.
- Murray EA, Richmond BJ** (2001) Role of perirhinal cortex in object perception, memory, and associations. *Curr. Opin. Neurobiol.* **11**, 188–193.
- Murre JM, Graham KS, Hodges JR** (2001) Semantic dementia: Relevance to connectionist models of long term memory. *Brain* **124**, 647–675.
- Nadel L, Moscovitch M** (1997) Memory consolidation, retrograde amnesia and the hippocampal complex. *Curr. Opin. Neurobiol.* **7**, 217–227.
- Nadel L, Moscovitch M** (1998) Hippocampal contributions to cortical plasticity. *Neuropharmacology* **37**, 431–439.
- Nadel L, Moscovitch M** (2001) The hippocampal complex and long-term memory revisited. *Trends Cogn. Neurosci.* **5**, 228–230.
- Nadel L, Ryan L, Hayes SM, Gilboa A, Moscovitch M** (2003) The role of the hippocampal complex in long-term episodic memory. In: *Limbic and Association Cortical Systems – Basic, Clinical and Computational Aspects* (eds Ono T, Matsumoto G, Llinas RR, Berthoz A, Norgen R, Nishijo H, Tamura R) Amsterdam, the Netherlands: Elsevier Science/Excerpta Medica International Congress Series.
- Nadel L, Samsonovich A, Ryan L, Moscovitch M** (2000) Multiple trace theory of human memory: Computational, neuroimaging, and neuropsychological results. *Hippocampus* **10**, 352–368.
- Nestor PJ, Graham KS, Bozeat S, Simons JS, Hodges JR** (2002) Memory consolidation and the hippocampus: Further evidence from the study of autobiographical memory in semantic dementia and the frontal variant of frontotemporal dementia. *Neuropsychologia* **40**, 633–654.
- Niki K, Luo J** (2002) An fMRI study on the time-limited role of the medial temporal lobe in long-term topographical autobiographic memory. *J. Cogn. Neurosci.* **14**, 500–507.
- O’Kane G, Kensinger EA, Corkin S** (2004) Evidence for semantic learning in profound amnesia: An investigation with patient H.M. *Hippocampus* **14**, 417–425.
- O’Keefe J, Nadel L** (1978) *The Hippocampus as a Cognitive Map*. Oxford, UK: Oxford University Press.
- Ogden JA** (1993) Visual object agnosia, prosopagnosia, achromatopsia, loss of visual imagery, and autobiographical amnesia following recovery from cortical blindness: Case MH. *Neuropsychologia* **31**, 571–589.
- Owen AM, Milner B, Petrides M, Evans AC** (1996a) Memory for object features versus memory for object location: a positron-emission tomography study of encoding and retrieval processes. *Proc. Natl. Acad. Sci. USA* **93**, 9212–9217.
- Owen AM, Milner B, Petrides M, Evans AC** (1996b) A specific role for the right parahippocampal gyrus in the retrieval of object-location: a positron emission tomography study. *J. Cogn. Neurosci.* **8**, 588–602.
- Penfield W, Milner B** (1958) Memory deficit produced by bilateral lesions in the hippocampal zone. *Arch. Neurol. Psychiatry* **79**, 475–497.
- Piefke M, Weiss PH, Zilles K, Markowitsch HJ, Fink GR** (2003) Differential remoteness and emotional tone modulate the neural correlates of autobiographical memory. *Brain* **126**, 650–668.
- Piolino P, Desgranges B, Belliard S, Matuszewski V, Lalevee C, De la Sayette V, et al.** (2003) Autobiographical memory and auto-nocuous consciousness: Triple dissociation in neurodegenerative diseases. *Brain* **126**, 2203–2219.
- Piolino P, Giffard-Quillon G, Desgranges B, Chetelat G, Baron J-C, Eustache F** (2004) Re-experiencing old memories via hippocampus: a PET study of autobiographical memory. *NeuroImage* **22**, 1371–1383.
- Ranganath C, Yonelinas AP, Cohen MX, Dy CJ, Tom SM, D’Esposito M** (2004) Dissociable correlates of recollection and familiarity within the medial temporal lobes. *Neuropsychologia* **42**, 2–13.
- Reed JM, Squire LR** (1998) Retrograde amnesia for facts and events: Findings from four new cases. *J. Neurosci.* **18**, 3943–3954.
- Rempel-Clower NL, Zola SM, Squire LR, Amaral DG** (1996) Three cases of enduring memory impairment after bilateral damage limited to the hippocampal formation. *J. Neurosci.* **16**, 5233–5255.
- Rockland KS, Van Hoesen GW** (1999) Some temporal and parietal cortical connections converge in CA1 of the primate hippocampus. *Cereb. Cortex* **9**, 232–237.
- Roediger HL, III, McDermott KB** (1993) In: *Handbook of Neuropsychology* (eds Spinnler H, Boller, F section ed. Cermak LS), pp. 63–131. Amsterdam, the Netherlands: Elsevier.
- Rosenbaum RS, Priselac S, Köhler S, Black SE, Gao F, Nadel L, et al.** (2000) Remote spatial memory in an amnesic person with extensive bilateral hippocampal lesions. *Nat. Neurosci.* **3**, 1044–1048.
- Rosenbaum RS, Winocur G, Moscovitch M** (2001) New views on old memories: Re-evaluating the role of the hippocampal complex. *Behav. Brain Res.* **127**, 183–197.
- Rosenbaum RS, Ziegler M, Winocur G, Grady CL, Moscovitch M** (2004a) I have often walked down this street before: fMRI studies on the hippocampus and other structures during mental navigation of an old environment. *Hippocampus* **14**, 826–835.
- Rosenbaum RS, McKinnon MC, Levine B, Moscovitch M** (2004b) Visual imagery deficits, impaired strategic retrieval, or memory loss: Disentangling the nature of an amnesic patient’s autobiographical memory deficit. *Neuropsychologia* **42**, 1619–1635.
- Rosenbaum RS, Gao FQ, Richards B, Black SE, Moscovitch M** (2005a) ‘Where to?’ Remote memory for spatial relations and landmark identity in former taxi drivers with Alzheimer’s disease and encephalitis. *J. Cogn. Neurosci.* **17**, 446–462.
- Rosenbaum RS, Köhler S, Schacter DL, Moscovitch M, Westmacott R, Black SE, et al.** (2005b) The case of K.C. Contributions of a memory-impaired person to memory theory. *Neuropsychologia* **43**, 989–1021.
- Rosenbaum RS, Winocur G, Grady CL, Ziegler M, Moscovitch M** (2005) fMRI studies of remote spatial memory in an amnesic person with bilateral hippocampal damage (submitted).
- Rotello CM, Macmillan NA, Reeder JA** (2004) Sum-difference theory of remembering and knowing: a two-dimensional signal-detection model. *Psychol. Rev.* **111**, 588–616.
- Rozin P** (1976) The psychobiological approach to human memory. In: *Neural Mechanisms of Learning and Memory* (eds Rozenzweig R, Bennett EL). Cambridge, MA, USA: MIT Press.

- Rubin DC, Greenberg DL** (1998) Visual memory deficit amnesia: a distinct amnesic presentation and etiology. *Proc. Natl. Acad. Sci. USA* **95**, 5413–5416.
- Ryan L, Nadel L, Keil K, Putnam K, Schnyer D, Trouard T, Moscovitch M** (2001) Hippocampal complex and retrieval of recent and very remote autobiographical memories: Evidence from functional magnetic resonance imaging in neurologically intact people. *Hippocampus* **11**, 707–714.
- Sanders HI, Warrington EK** (1971) Memory for remote events in amnesic patients. *Brain* **94**, 661–668.
- Schacter DL** (1987) Implicit memory: History and current status. *J. Exp. Psychol. Learn. Mem. Cogn.* **13**, 501–518.
- Schacter DL, Badgaiyan RD** (2001) Neuroimaging of priming: New perspectives on implicit and explicit memory. *Curr. Directions Psychol. Sci.* **10**, 1–4.
- Schacter DL, Buckner RL** (1998) Priming and the brain. *Neuron* **20**, 185–195.
- Schacter DL, Dobbins IG, Schnyer DM** (2004) Specificity of Priming: a cognitive neuroscience perspective. *Nat. Rev. Neurosci.* **5**, 853–862.
- Schacter DL, Eich JE, Tulving E** (1978) Richard Seemon's theory of memory. *J. Verbal Learn. Verbal Behav.* **17**, 721–743.
- Schacter DL, Tulving E** (1994) *Memory Systems 1994*. Cambridge, MA, USA: MIT/Bradford Press.
- Scoville WB, Milner B** (1957) Loss of recent memory after bilateral hippocampal lesions. *J. Neurol. Neurosurg. Psychiatry* **20**, 11–21.
- Semon R** (1922) *The Mneme*. London, UK: George Allen & Unwin.
- Shimamura AP** (2002) Relational between binding theory and the role of consolidation in memory retrieval. In: *Neuropsychology of Memory*, 3rd edn (eds Squire LR, Schacter, DL), pp. 61–72. New York, USA: Guilford Press.
- Skotko B, Kensinger EA, Locascio JJ, Einstein JG, Ruin DC, Tupler LA, et al.** (2004) Can new semantic memories be anchored to old semantic memories? *Neuropsychology* **18**, 756–769.
- Snowden JS, Griffiths HL, Neary D** (1994) Semantic dementia: Autobiographical contribution to preservation of meaning. *Cogn. Neuropsychol.* **11**, 265–288.
- Snowden JS, Griffiths HL, Neary D** (1996) Semantic–episodic memory interactions in semantic dementia: Implications for retrograde memory function. *Cogn. Neuropsychol.* **13**, 1101–1137.
- Snowden JS, Neary D** (2002) Relearning of verbal labels in semantic dementia. *Neuropsychologia* **40**, 1715–1728.
- Squire LR** (1975) A stable impairment in remote memory following electroconvulsive therapy. *Neuropsychologia* **13**, 51–58.
- Squire LR** (1992) Memory and the hippocampus: a synthesis from findings with rats, monkeys and humans. *Psychol. Rev.* **99**, 195–231.
- Squire LR, Alvarez P** (1995) Retrograde amnesia and memory consolidation: a neurobiological perspective. *Curr. Opin. Neurobiol.* **5**, 169–177.
- Squire LR, Cohen NJ, Nadel L** (1984) The medial temporal region and memory consolidation: A new hypothesis. In: *Memory Consolidation* (eds Weingartner H, Parker E), pp. 185–210. Hillsdale, NJ, USA: Lawrence Erlbaum Associates.
- Squire LR, Stark CE, Clark RE** (2004) The medial temporal lobe. *Annu. Rev. Neurosci.* **27**, 279–306.
- Squire LR, Zola SM** (1998) Episodic memory, semantic memory, and amnesia. *Hippocampus* **8**, 205–211.
- Steinvorth S, Levine B, Cokin S** (2005) Medial temporal lobe structures are needed to re-experience remote autobiographical memories: Evidence from H.M. & W.R. *Neuropsychologia* **43**, 479–496.
- Suengas AG, Johnson MK** (1988) Qualitative effects of rehearsal on memories for perceived and imagined complex events. *J. Exp. Psychol. General* **117**, 377–389.
- Suzuki WA, Amaral DG** (1994) Perirhinal and parahippocampal cortices of the macaque monkey: cortical afferents. *J. Comp. Neurol.* **350**, 497–533.
- Takahashi N, Kawamura M, Shiota J, Kasahata N, Hirayama K** (1997) Pure topographic disorientation due to right retrosplenial lesion. *Neurology* **49**, 464–469.
- Talairach J, Tournoux P** (1988) *Co-Planar Stereotaxic Atlas of the Human Brain*. New York, USA: Thieme Medical Publishers.
- Teng E, Squire LR** (1999) Memory for places learned long ago is intact after hippocampal damage. *Nature* **400**, 675–677.
- Teyler TJ, DiScenna P** (1986) The hippocampal memory indexing theory. *Behav. Neurosci.* **100**, 147–154.
- Thompson-Schill S** (2003) Neuroimaging studies of semantic memory: inferring 'how' from 'where'. *Neuropsychologia* **41**, 280–292.
- Tranel D, Damasio H, Damasio AR** (1997) A neural basis for the retrieval of conceptual knowledge. *Neuropsychologia* **35**, 1319–1327.
- Tulving E** (1972) Episodic and semantic memory. In: *Organization of Memory* (eds Tulving E, Donaldson W), pp. 381–403. New York, USA: Academic Press.
- Tulving E** (1985) Memory and consciousness. *Can. Psychologist* **25**, 1–12.
- Tulving E, Craik FIM** (2000) *The Oxford Handbook of Memory*. Oxford, UK: Oxford University Press.
- Tulving E, Schacter DL** (1990) Priming and human memory systems. *Science* **247**, 301–306.
- Van der Linden M, Cornil V, Meulemans T, Ivanoiu A, Salmon F, Coyette F** (2001) Acquisition of a novel vocabulary in an amnesic patient. *Neurocase* **7**, 283–293.
- Van Hoesen GW, Morecraft RJ, Vogt BA** (1993) Connections of the monkey cingulate cortex. In: *Neurobiology of Cingulate Cortex and Limbic Thalamus: a Comprehensive Handbook* (eds Vogt BA, Gabriel M), pp. 249–284. Boston, MA, USA: Birkhauser.
- Vargha-Khadem F, Gadian DG, Watkins KE, Conneley A, Van Paesschen W, Mishkin M** (1997) Differential effects of early hippocampal pathology on episodic and semantic memory. *Science* **277**, 376–380.
- Viskontas IV, McAndrews MP, Moscovitch M** (2000) Remote episodic memory deficits in patients with unilateral temporal lobe epilepsy and excisions. *J. Neurosci.* **20**, 5853–5857.
- Vogt BA, Vogt LJ, Perl DP, Hof PR** (2001) Cytology of human caudomedial cingulate, retrosplenial, and caudal parahippocampal cortices. *J. Comp. Neurol.* **438**, 353–376.
- Wagner AD, Paré-Blagoev EJ, Clark J, Poldrack RA** (2001) Recovering meaning: Left. Prefrontal cortex guides controlled semantic retrieval. *Neuron* **31**, 329–338.
- Warrington EK** (1996) Studies of retrograde memory: a long-term view. *Proc. Natl. Acad. Sci.* **93**, 13523–13526.
- Warrington EK, McCarthy RA** (1988) The fractionation of retrograde amnesia. *Brain Cogn.* **7**, 184–200.

- Warrington EK, Sanders HI** (1971) The fate of old memories. *Q. J. Exp. Psychol.* **23**, 432–442.
- Warrington EK, Weiskrantz L** (1970) Amnesic syndrome: Consolidation or retrieval? *Nature* **228**, 628–630.
- Weiskrantz L** (1980) Varieties of residual experience. *Quarterly Journal of Experimental Psychology* **32**, 365–386.
- Westmacott R, Freedman M, Black SE, Stokes KA, Moscovitch M** (2004a) Temporally graded semantic memory loss in Alzheimer's Disease: Cross-sectional and longitudinal studies. *Cogn. Neuropsychol.* **21**, 353–378.
- Westmacott R, Black SE, Freedman M, Moscovitch M** (2004b) The contribution of autobiographical significance to semantic memory: Evidence from Alzheimer's disease, semantic dementia, and amnesia. *Neuropsychologia* **42**, 25–48.
- Westmacott R, Leach L, Freedman M, Moscovitch M** (2001) Different patterns of autobiographical memory loss in semantic dementia and medial temporal lobe amnesia: a challenge to consolidation theory. *Neurocase* **7**, 37–55.
- Westmacott R, Moscovitch M** (2001) Names and words without meaning: Incidental post-morbid semantic learning in a person with extensive bilateral medial temporal lobe damage. *Neuropsychology* **15**, 586–596.
- Westmacott R, Moscovitch M** (2002) Temporally graded semantic memory loss in amnesia and semantic dementia: Further evidence for opposite gradients. *Cog. Neuropsych.* **19**, 135–163.
- Westmacott R, Moscovitch M** (2003) The contribution of autobiographical significance to semantic memory. *Mem. Cogn.* **31**, 761–774.
- Whiteley AM, Warrington EK** (1978) Selective impairment of topographical memory: a single case study. *J. Neurol. Neurosurg. Psychiatry* **41**, 575–578.
- Wiggs CL, Martin A** (1998) Properties and mechanisms of perceptual priming. *Curr. Opin. Neurobiol.* **8**, 227–233.
- Vinocur G, Moscovitch M, Fogel S, Rosenbaum RS, Sekeres M** (2005) Preserved spatial memory after hippocampal lesions: effects of extensive experience in a complex environment. *Nature Neuroscience* **8**, 273–275.
- Yonelinas AP** (2002) The nature of recollection and familiarity: a review of 30 years of research. *J. Mem. Lang.* **46**, 441–517.
- Yonelinas AP, Kroll NE, Quamme JR, Lazzara MM, Sauve M-J, Widaman KF, et al.** (2002) Effects of extensive temporal lobe damage or mild hypoxia on recollection and familiarity. *Nat. Neurosci.* **5**, 1236–1241.